

CASE REPORT

Sudden Visual Impairment in Sellar Region Tumor : A Case of Pituitary Apoplexy

Anindita Wicitra, Syntia Nusanti, M Sidik

Departement of Ophthalmology, Faculty of Medicine, Universitas Indonesia, Jakarta
Cipto Mangunkusmo Hospital, Jakarta
E-mail: wicitraanindita@gmail.com

ABSTRACT

Objective : Pituitary apoplexy described as an acute hemorrhagic infarction of the pituitary adenoma causing sudden increase of intra sellar pressure. This condition is a life-threatening disease. The purpose of this article is to report about clinical symptom and methods to diagnose pituitary apoplexy.

Case Presentation : A 40 y.o male came with a complain of blurry vision since 1 year. Two months before admission, he felt sudden worsening of his visual acuity. He went to private hospital and there was bleeding in his brain CT scan. His right eye visual acuity was 1/300 and his left best visual acuity was 6/12. Relative afferent pupillary defect was positive in the right eye. In fundoscopic examination, both of optic nerve head were atrophy. Left eye visual field examination revealed temporal hemianopsia. Cerebral MRI showed a hyper intense lesion on both T1WI and T2WI sequence in sellar region that extends into supra sellar region with sign of sellar floor ballooning. The result of MRI contrast was relatively same and the hormonal exam result was within normal limit. Then he was scheduled for removal tumor surgery from neurosurgery departement.

Conclusion : Pituitary apoplexy is a severe clinical syndrome and life-threatening disease. To rule out other disease presenting related symptoms, many ancillary examinations are require to be performed. The treatment of pituitary apoplexy, whether to treat surgically or conservatively, should be made by experts from a multidisciplinary team.

Keywords: *bitemporal hemianopsia, pituitary apoplexy, sudden visual loss, sudden visual defect*

Pituitary adenoma is a benign epithelial tumor derived from the adenohypophysial cells of the pituitary gland. This disease contributes for about 15% of intracranial neoplasms with a prevalence of about 80-90 cases per 100,000.¹ These types of tumor usually grow slowly unless pituitary apoplexy is occurred. Pituitary apoplexy described as acute hemorrhagic infarction of the pituitary adenoma causing sudden increase of intra sellar pressure, resulting in acute onset of headache, vomiting, nausea, visual

loss, ophthalmoplegia, and even pan-hypopituitarism.^{2,3}

Pituitary apoplexy is a rare life-threatening condition and its incidence is difficult to establish. Sudden enlargement of a tumorous pituitary gland and rapid expansion into the cavernous sinus can cause increasing intracranial pressure and can lead to death.⁴ In this paper we report about clinical symptom and methods to diagnose patient with pituitary apoplexy. Because the management for this disease is

still challenging, better understanding of pituitary apoplexy is essential.

CASE PRESENTATION

Forty-year-old male came to neuro-ophthalmology clinic with a chief complain blurry vision since 1 year before admission. The condition was getting worse but he still can see. There was no dizziness, headache, seizure or vomiting. Two months before admission he felt sudden worsening of his visual acuity on his both eyes. This complaint started at his right eye and then followed by the other eye. He underwent brain CT scan and the result was bleeding in his brain. There was no history of head or eye trauma before.

On physical examination, the patient was compos mentis. Examination from motoric, sensory, and autonomic nerve system was within normal limit. No sign of increase blood pressure. Visual acuity on his right eye was hand movement wrong projection, and his left eye visual acuity was 6/12 with spherical correction. Eye movement was good to all direction and both eyes were orthophoria. Ocular examination in anterior segment was within normal limit. There was a positive sign of RAPD in the right eye. In fundusoscopic examination, both of nerve head were atrophy (fig.1).

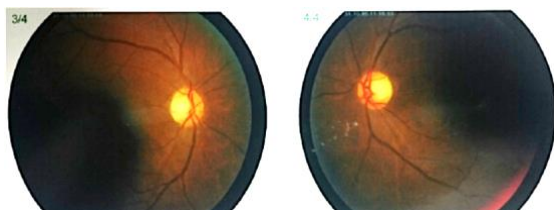


Fig 1. Fundus photo of patient's both eyes showed optic disc atrophy

Visual field examination on the left eye revealed decrease visual field in temporal region (fig.2). The cerebral MRI result was a hyper intense lesion on both T1WI and T2WI sequence in sellar region that extends into supra sellar region with sign of sellar floor ballooning. We consult this patient to neurosurgery department, they plan to

check hormonal examination cortisol, TSH, FSH, LH and Brain MRI with contrast. MRI contrast revealed tumor in sellar region with bleeding and the size was relatively same if compared to the last MRI (fig.3) and the hormonal exam result was within normal limit. From neurosurgery department, the patient was schedule for removal tumor surgery.

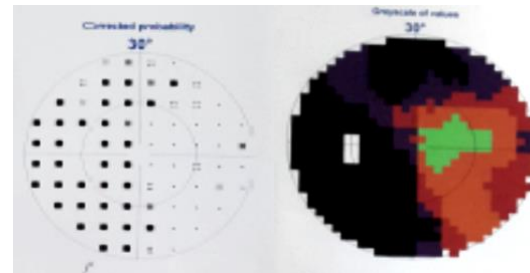


Fig 2. Octopus examination of patient's left eye showed temporal hemianopsia

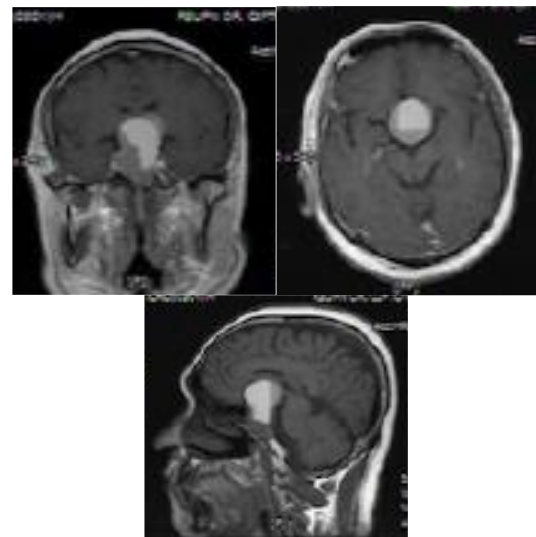


Fig 3. MRI contrast showed tumor in sellar region with hemorrhage

DISCUSSION

Pituitary adenoma is a benign tumor caused by hyperplasia of anterior pituitary cells. This condition may present at any age, but rarely occurred in childhood.^{6,7} After forth decade of life, the incidence of pituitary adenoma was increasing.⁵ Most of pituitary adenomas (about 70%) occur in patient aged 30-50 years old and have no sexual predominance.^{8,9} Pituitary adenoma is usually presented with symptoms including

decrease of visual field, chronic or subacute visual loss, and headache. Diplopia, symptomatic proptosis, vomiting, weight loss and facial swelling were also reported on patient with pituitary adenoma. Clinical findings in pituitary adenomas including bitemporal hemianopia, decrease of visual acuity, afferent pupillary defect, optic disc pallor, ptosis, proptosis, third nerve palsy, and sixth nerve palsy.⁸ Endocrine parameters can be found within normal range in pituitary adenoma but may also be presented with abnormal hormonal findings.⁹

Diplopia and ophthalmoplegia due to compression of the adjacent ocular motor nerves is commonly found in patient with pituitary apoplexy. Chiasmal field loss accompanied by an ocular motor palsy indicates cavernous sinus involvement. The degree of ophthalmoplegia may also be asymmetrical and variable, varying on the area of involvement of each cavernous sinus.^{3,8,23} In this patient, there was no ophthalmoparesis and diplopia. This condition reveals that there was no involvement of cavernous sinus.

Long standing progressions of pituitary adenoma can cause optic disc pallor. Optic disc pallor and retinal nerve fibre layer damage are related with a poorer prognosis for visual improvement following treatment.⁹ From ophthalmologic examination, there was optic disc atrophy in our patient. This finding correlates with long term compression of pituitary tumor in optic nerve, therefore he has a poor prognosis for his visual outcome even after the given therapy.

Pituitary adenoma will progress slowly unless pituitary apoplexy is happened. Pituitary apoplexy is an acute hemorrhage or infarction of the pituitary tumor. This condition is a potentially life-threatening incident.^{6,7} About 2% of pituitary adenomas will be presented apoplectically.⁹ Study held by Weed MC et al analysed that incidence of apoplexy varies between 0,6% - 10% in all pituitary adenoma.⁷ Another study by Schatz NJ et al

reported the incidence of pituitary apoplexy was higher, about 10-15% from all case of pituitary adenoma.¹⁰

This patient complained about sudden visual loss in his right eye. RAPD was also found in his right eye with optic disc atrophy on his both eyes. Patients with pituitary apoplexy will have a RAPD and reduced color vision.¹³ A damaged optic nerve may contribute to more central loss, with reduced visual acuity, dyschromatopsia, and an RAPD on the affected region. Significant asymmetric visual field defect without direct optic nerve injury may also generate a RAPD.⁶ Almost all patients with pituitary apoplexy has a pale optic nerve and complain of decreased visual acuity.^{9,13} Initially, optic discs may show no detectable damage even when the patient complain about his visual field loss. With additional damage, the optic disc showed typical atrophy, usually in the temporal region of the disc related to the papillomacular bundle of retinal nerve fibers and the nasal fibers.⁶ Chronic compression of chiasm in more than 6 weeks usually induces nerve fibre layer damage or optic atrophy. This condition also may be a delayed indication of chiasmal compression and is correlated with a poorer postoperative visual acuity.^{5,6}

Visual field tests may provide a strong indication of direct chiasmal involvement.⁵ The most significant neuro-ophthalmology finding of pituitary adenomas is chiasmal visual field loss. In early chiasmal compression, visual field often lacks a clear vertical defect. This condition usually occur slowly progressive and insidious.^{5,9} Most often, temporal paracentral depression occurs because the chiasm has macular projections through most areas. Even though, any type of visual field defect may be present in patient with pituitary apoplexy.¹³ We did octopus examination to detect any visual field defect. The result was decreased visual field in temporal region in the left eye but visual field in right eye cannot be examined because of the poor visual acuity.

Patient with pituitary apoplexy should undergo radiology examination to confirm the diagnosis. Magnetic Resonance Imaging (MRI) is the modality of choice and can show a presence of pituitary mass and blood products varying on the stages of hemorrhage. MRI could show us the mass size, primary mass lesions, presence of infarction or hemorrhage, and compression on optic chiasm or cavernous sinuses. T2 slice with Gradient Recalled Echo (GRE) as the most sensitive sequence in MRI to diagnose pituitary apoplexy.¹⁵ Many lesions in parasellar can present with hyperintensity on T1WI in the sellar region, as the most common MRI sign of pituitary apoplexy.^{20,21} Fluid level appearance in MRI indicates the presence of hemorrhage of differing periods. Another advantages from MRI is it capable of determining the estimated periods of these bleeds.^{15,16} Computerized Tomography (CT) can be used as a primary imaging modality, especially in emergency cases. CT may show a sellar and suprasellar mass, however MRI may reveal a heterogeneous or homogeneous mass in the sella region.¹⁷

Management of pituitary apoplexy is essentially multidisciplinary team, including neurosurgery, endocrine, and ophthalmology department.^{24,25,26} Early diagnosis and prompt treatment is important to avoid complications and prevent persistent ophthalmic and neurological deficits. Still, management of pituitary apoplexy is a substance of controversy.²⁷ Management and treatment will change depending on the degree of development, capability of the patient to tolerate surgical intervention, the need for continuous hormone suppression or substitution, potential efficacy of preoperative medical therapy based on tumor subtype, and use of for post-operative radiation treatment in cases of insufficient tumor resection.¹⁷

Patients with pituitary apoplexy with mild or without any neuro-ophthalmic signs and stable symptoms can be considered for conservative treatment with strict monitoring.²⁶ Patient with severe neuro-ophthalmologic involvement

affecting visual acuity and or visual field, altered consciousness, chiasm compression or focal neurological signs was candidate for surgical decompression.^{24,27,28} In addition, disturbance of III, IV or VI cranial nerves without decreased visual acuity or any visual field limitation is not an indication for emergency surgery.²⁶ All patients who have been treated need long-term follow-up imaging to detect persistent growth. An MRI scan is suggested to be performed at 3–6 months after treatment and afterwards an annual MRI scan examination should be done for the next 5 years, then two yearly.²⁶

CONCLUSION

Many ancillary examinations are needed to confirm the diagnoses of Pituitary Apoplexy. The treatment of pituitary apoplexy should be made by experts from a multidisciplinary team.

REFERENCES

1. Naguib MM, Mendoza PR, Jariyakosol S, and Grossniklaus HE. Atypical Pituitary Adenoma with Orbital Invasion: Case Report and Review of the Literature. *Survey of Ophthalmology*. 2017; P.1-23.
2. Saffra et al.: Isolated sixth cranial nerve palsy as the presenting symptom of a rapidly expanding ACTH positive pituitary adenoma: a case report. *BMC Ophthalmology*. 2011;11(4); 1-4.
3. Brad Bowling. Neuro-ophthalmology. In: Kanski's Clinical Ophthalmology, 8th ed. Philadelphia: Elsevier.2016. p.773-849.
4. Murad-Kejbou S and Eggenberger E. Pituitary apoplexy: evaluation, management, and prognosis. *Current Opinion in Ophthalmology*. 2009; 20; 456 – 61.
5. Rubin RM, Sadun AA, and Piva AP. Optic Chiasm, Parasellar Region, and Pituitary Fossa. In: *Ophthalmology*, fourth edition. Philadelphia: Elsevier. 2014. P. 900-8.
6. American Academy of Ophthalmology. The Patient With Decreased Vision: Classification and Management. American Academy of Ophthalmology, editor. Neuro-ophthalmology. San Francisco: American Academy of Ophthalmology; 2011-2012. p. 162-4.
7. Weed MC, Longmuir RA, Thurtell MJ. Pituitary Adenoma Causing Compression of the Optic Chiasm: 49-year-old white female with painless progressive vision loss. *EyeRounds*. 2013.

8. Peter A. Quiros. Urgent neuro-ophthalmic disorders. In: *Ophthalmology*, fourth edition. Philadelphia: Elsevier. 2014. P 983-7.
9. Grant T. Liu MD, Nicholas J. Volpe MD and Steven L. Galetta MD. Vision loss: disorders of the chiasm. In: *Neuro-Ophthalmology: Diagnosis and Management*. Philadelphia: Elsevier. 2010. P.237-91.
10. Schatz NJ, Job OM, and Glaser JS. Spontaneous Resolution of Pituitary Adenoma After Apoplexy. *Journal of Ophthalmology*. 2000; 20(1): 42-4.
11. Zhu X, et al. Incidence of Pituitary Apoplexy and Its Risk Factors in Chinese People: A Database Study of Patients with Pituitary Adenoma. *PLoS ONE*. 2015; 10(9); P 1-12.
12. Joseph F, Lockhat ZI, Smal J, and Moja TP. Acute pituitary apoplexy complicating a pituitary macroadenoma. *SA Journal Of Radiology*. 2010; 118-21.
13. Atkins EJ, Newman NJ, and Bioussé V. Lesions of the optic nerve. *Handbook of Clinical Neurology. Neuro-ophthalmology*. Philadelphia: Elsevier. 2011; P.159-84.
14. Danesh-Meyer HV, et al. In vivo retinal nerve fiber layer thickness measured by optical coherence tomography predicts visual recovery after surgery for parachiasmal tumors. *Invest Ophthalmol Vis Sci*. 2008; 49; 1879–85.
15. Tantiwongkosi B and Mafee M. Imaging of Optic Neuropathy and Chiasmal Syndromes. *Neuroimag Clin N Am*. 2015; 25; 395–410.