

## ORIGINAL ARTICLE

# The Pattern of Increasing Intraocular Pressure after Phakic Anterior Chamber Intraocular Lens Implantation

Puty Lestari, Widyandana, Agus Supartoto

Department of Ophthalmology, Faculty of Medicine, Universitas Gadjah Mada  
Sardjito General Hospital, Yogyakarta  
Email : putylestari@gmail.com

## ABSTRACT

**Background:** Phakic intraocular lenses (IOL) are being used to correct refractive errors. We studied the pattern of increasing Intraocular Pressure (IOP) after Phakic Anterior chamber intraocular lens implantation as the risk after surgery.

**Methods:** Sixty eyes of 30 patients were enrolled. All eyes underwent the same protocol with IOP examination before surgical procedure, and during follow up (one day after, 2 weeks, 1 month, 2 months and 3 months) after implantation of phakic IOL anterior chamber. All results were analyzed statistically using SPSS 16 statistics software. Correlation between parameter were analyzed using the wilcoxon test.

**Results:** Median IOP before surgery were 14.00 mmHg (IOP), during follow up 17.00 mmHg (IOP I), 16.00 mmHg (IOP II), 17.00 mmHg (IOP III), 15.00 mmHg (IOP IV), 15.00 mmHg (IOP V). The increasing of IOP between pre surgery and follow up a day after was found to correlate significantly ( $p=0.03$ ), there were increasing of IOP after 2 weeks, a month, 2 and 3 months but no significant difference.

**Conclusion:** There were significant of increasing IOP before surgery compare to a day after surgery, then the pattern of increasing IOP tend to be stable. There were no significant increasing of IOP during 3 months follow up.

**Keywords:** Phakic IOL, Anterior Chamber, Intraocular Pressure, Increasing IOP, Implantation lens

Phakic intraocular lenses (PIOL) are clear implantable lenses that are surgically placed either in anterior chamber (AC) or posterior chamber (PC) without removing the natural lens, enabling light to focus on the retina for improved uncorrected visual acuity.<sup>1,2</sup>

Photorefractive keratectomy and LASIK may have limitations when used for the correction of high refractive errors. Wound healing and biomechanical responses can occasionally lead to poor refractive predictability, prolonged visual

recovery, instability of refraction, and loss of vision from corneal irregularity or scarring. Removing too much corneal tissue with the laser can induce progressive ectasia.<sup>2,3</sup> Two basic intraocular refractive procedures exist: phakic intraocular lens (PIOL) implantation and clear lens extraction with lens implantation, also called refractive lens exchange. The iris-fixated lens, on the other hand, is stabilized further from the cameral angle, corneal endothelium and crystalline lens, being the most implanted pIOL

today. Another advantage is optical: the claw principle guarantees centering of the lens over the pupil, and rotational stability, which is especially important for toric lenses.<sup>3</sup> The risks and benefits of pIOL implantation in appropriate patients may be more favorable than other refractive surgery techniques. The pIOL is removable surgically, Visual recovery is fast, and accommodation is preserved, Implantation of a pIOL utilizes operative techniques familiar to most cataract surgeons and does not require expensive or specialized devices.<sup>3-4</sup> Complications relating to pIOLs can be more disabling than those from keratorefractive surgery. Potential complications following implantation of phakic intraocular lenses include The main complications of iris-fixated anterior chamber pIOLs are chronic subclinical inflammation, corneal endothelial cell loss, cataract formation, secondary glaucoma, iris atrophy and dislocation.<sup>3-5</sup> A variety of causes have been implicated in case reports of high IOP after phakic intraocular lens implantation. Raised IOP following implantation can be seen in the early or late post operative period. The rate of occurrence of raised IOP as reported in literature ranges from 0.8% to 26.2%. We studied the pattern of increasing Intraocular Pressure (IOP) after Phakic Anterior chamber intraocular lens implantation (Artisan®/Artiflex®) phakic intraocular lenses (pIOLs) as a complication after surgery that may lead to secondary glaucoma.<sup>4-5</sup>

## METHOD

In all, 60 eyes of 30 patients had surgeries at the YAP Eye Hospital, Jogjakarta Indonesia, from January to December 2016. All of the patients were fully informed about the details of the procedures and the risks involved, and were given informed consents to sign. Patient's age and gender were recorded. Inclusion criteria: (1) Stable refraction (less than 0.5D change for 1 year); (2) clear crystalline lens; (3) ametropia not appropriate for excimer laser surgery; (4) unsatisfactory vision with contact lenses or spectacles; (5) appropriate pupil size for the specified PIOL; (6) adequate anterior chamber

depth (ACD); (7) minimum endothelial cell count (ECC); Exclusion criteria: Subjects with (1) anisometropia; (2) anterior segment pathology; (3) inadequate eyelid closure; (4) ECC <1800 cells/mm<sup>2</sup>; (5) central ACD <3.0 mm; (6) abnormal iris or pupil function; (7) intraocular pressure (IOP) >21 mm Hg; (8) previous corneal or intraocular surgery; (9) any intraocular eye disease such as recurrent or chronic uveitis, cataract, glaucoma, or family history of glaucoma, retinal detachment or family history of retinal detachment, preexisting macular degeneration or macular pathology; (10) systemic diseases, chronic treatment with corticosteroids or any immunosuppressive treatment or state, and pregnancy. Patients with raised IOP were identified using the following criteria: IOP elevation equal to or greater than 21 mmHg, in this study we describe the pattern of IOP by 1 day, 2 weeks, 1 month, 2 months and 3 months period of follow up.

## SURGICAL TECHNIQUE

Thirty minutes before the operation, the mitotic drop (1% pilocarpine) was given every 5 min, 3 times, then topical anesthetic was given three times. A superior sclerocorneal self-sealing 5.3-mm to 5.5-mm incision and two paracenteses were created. A cohesive ophthalmic viscosurgical device (sodium hyaluronate 1%) was injected through the paracenteses to maintain ACD and protect endothelial cells. Further, the IOL was placed into the anterior chamber and was enclavated onto the iris, after which the visco surgical device was removed. All eyes underwent a peripheral iridotomy during the operation.

All subjects underwent a comprehensive preoperative evaluation at YAP Eye Specialist Hospital. IOP was measured primarily with a Non Contact Tonometer at one day, 2 weeks, 1 month, 2 months and 3 months post-operation.

The primary outcome measure was intraocular pressure during the period of follow up.

Statistical analysis was performed on the intent to treat basis using SPSS version 16 software. The 95% confidence interval (CI) values were calculated for each mean. A value <0.05 was considered statistically significant.

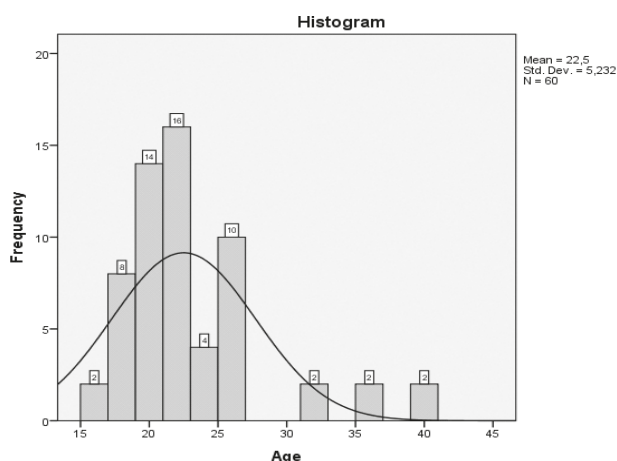
## RESULTS

A total of 8 (13.3 %) myopic eyes that underwent iris-fixated iol implantation developed elevated IOP on the first postoperative day. The following amount of eyes developed elevated IOP within respective time periods: 1 eye within 2 weeks, 7 eyes within 1 month, and 4 eyes after 3 months. Demographic data and baseline characteristics of the study patients are presented in Table 1. Most patients were male 16 (53.3%) and female 14 (46.7%) and the age mean was  $22.5 \pm 5$ . Preoperatively, The median preoperative IOP was  $14.00 \pm 3.44$  mmHg (range 6–21 mmHg). None of the eyes had a history of elevated IOP or documentation of IOP elevation preoperatively.

There were increasing of IOP at day 1 after surgical and 1 month after. Then we correlate the increasing of IOP during follow up and the IOP pre operatif as the control. IOP day 1 (IOP I), IOP 2 weeks (IOP II), IOP 1 month (IOP III), IOP 2 month (IOP IV) and IOP 3 month (IOP V). We correlate the increasing of IOP between pre surgery (IOP) and IOP After term of follow up by Using Wilcoxon Test. There was significantly increasing of IOP between pre surgery and the day after surgery with  $p < 0.003$ .

**Table 1.** Demographic data and baseline characteristic of patients

Variable	Numbers
Number of patients	30
Number of eyes	60
Sex Male	16 (53.3%)
Female	14 (46.7%)
Age (Mean)	$22,5 \pm 5.2$



**Figure 1.** Distribution of patients based on age

## DISCUSSION

The Iris Fixated lens pIOL rarely can induce glaucoma compare with the angle supported IOL. The iris-fixated anterior IOL was fixated on the iris, avoiding the trabecular meshwork damage.<sup>5-7</sup> Preoperative iridotomy or an intraoperative iridectomy can avoid the pupil block, and thus, in this study, all eyes underwent peripheral iridotomy during the operation. Transitory increase in IOP after operation after surgery was observed, possible mechanisms of raised IOP in this study, first due to Retained viscoelastic or overflow of the anterior chamber presents in the immediate postoperative period and often resolves with short course of antiglaucoma and anti-inflammatory medications. Second due to steroidal eye drops, Steroid induced IOP rise is reported as one of the commonest causes of elevated IOP following phakic IOL implantation, occurring within 1–4 weeks.<sup>7-9</sup>

There were 4 eyes with persistent raise of IOP during the 3 months follow-up. It was later found due to the possibility of chronic inflammation.

Pupillary block can also occur in patients with anterior chamber IOLs, either by direct blockage by the optic or by the adhesions between vitreous and posterior iris, but none was observed in this study [9-11]. The increased IOP between pre surgery (IOP) and the follow-up a day after (IOP I), 2 weeks (IOP II), a month (IOP III), 2 months (IOP IV) and 3 months (IOP V) were correlated using Wilcoxon Test.

There was a significant increase of IOP between pre-surgery and the day after surgery with  $p < 0.003$ . It was shown that the increase in IOP only occurred after Iris fixated IOL at day 1 post-surgery. Due to the retaining property of the viscoelastics, in this study we used sodium hyaluronate 1% as viscoelastic. The literature showed that Elevated IOP was due to retained viscoelastics that is more common in high viscous ocular viscoelastic devices (OVD) like Sodium hyaluronate in comparison to hydroxyl propyl methyl cellulose (HPMC). In a series by Almalki et al, retained OVD was responsible for elevated IOP in the majority of the cases (39.7%) followed by the steroid response (37.9% eyes).<sup>19</sup>

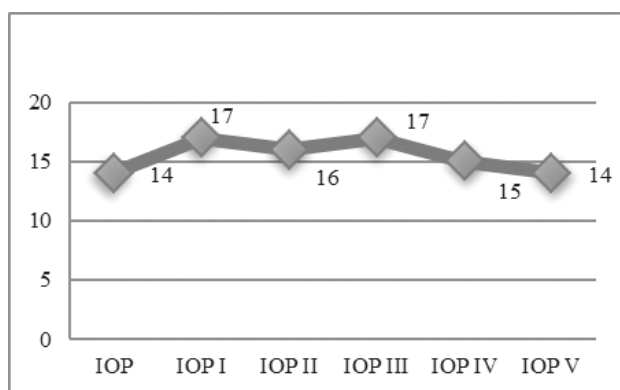
Irrigating out the viscoelastic instead of irrigation and aspiration was one of the reasons for increased incidence of retained viscoelastic and high IOP in their series. However, the IOP was normalized with short term Anti-Glaucoma Medication, without the need for long term medication for IOP control.<sup>3,11</sup>

**Table 2.** Mean and Median of IOP from Follow up Duration

Variable	Number	Range
IOP		
Mean	14.35±3.44	6-21
Median	14.00	
IOP I		
Mean	17.95±7.34	5-42
Median	17	
IOP II		
Mean	15.9±3.3	10-25
Median	16	
IOP III		
Mean	16.56±4.75	8-27
Median	17	
IOP IV		
Mean	14.6±3.0	9-20
Median	15	
IOP V		
Mean	16.45±7.5	10-41
Median	14	

**Table 3.** Comparison of Increasing IOP between before and after Phakic IOL

Parameter	Sig. (p<0.05)
Pair 1 IOP & IOP I	.003
Pair 2 IOP & IOP II	.105
Pair 3 IOP & IOP III	.148
Pair 4 IOP & IOP IV	.679
Pair 5 IOP & IOP V	.562



**Figure 2.** Pattern of Increasing IOP after phakic intraocular lens

## CONCLUSION

There was a significant increase in IOP before surgery in comparison to a day after surgery. After which, the pattern tends to be stable. There was no significant increase in IOP during 3 months of follow-up.

Our data demonstrated that the iris- fixated pIOL implantation is a safe and predictable option in reversible procedure for high myopia treatment and it is an effective of refractive surgery.

## REFERENCES

- Huang D, Schallhorn SC, Sugar A, Farjo AA, Majmudar PA, Trattler WB, Tanzer DJ (2009) Phakic intraocular lens implantation for the correction of myopia: a report by the Academy of Ophthalmology. *Ophthalmology* 116:2244–2258
- Fernandes P, Gonzalez-Mejome JM, Madrid-Costa D, Ferrer-Blasco T, Jorge J, Montes-Mico R. Implantable collamer posterior chamber intraocular lenses: a review of potential complications. *Journal of refractive surgery*. 2011; 27(10):765–76. doi: 10.3928/1081597X-20110617-01 PMID: 21710954
- Almalki S, Abubaker A, Alsabaani NA, Edward DP. Causes of elevated intraocular pressure following implantation of phakic intraocular lenses for myopia. *Int Ophthalmol* 2016; 36(2):259–65. doi: 10.1007/s10792-015-0112-4 PMID: 26265323
- Chang DF1, Tan JJ, Tripodis Y. Risk factors for steroid response among cataract patients. *J Cataract Refract Surg* 2011; 37(4):675–81. doi: 10.1016/j.jcrs.2010.10.051 PMID: 21420592
- Koivula A, Taube M, Zetterstrom C. Phakic refractive lens: two-year results. *J Refract Surg* 2008; 24 (5):507–15. PMID: 18494344
- Gierek-Ciaciura S, Gierek-Lapinska A, Ochalik K, Mrukwa-Kominek E. Correction of high myopia with different phakic anterior chamber intraocular lenses: ICARE angle-supported lens and Verisyse iris-claw lens. *Graefes Arch Clin Exp Ophthalmol* 2007;245:1–7.
- Jimenez-Alfaro I, Garcia-Feijoo J, Perez-Santonja JJ, Cuina R. Ultrasound biomicroscopy of ZSAL-4 anterior chamber phakic intraocular lens for high myopia. *J Cataract Refract Surg* 2001;27:1567–73.
- El Danasoury MA, El Maghraby A, Gamali TO. Comparison of iris-fixed Artisan lens implantation with excimer laser in situ keratomileusis in correcting myopia between □9.00 and □19.50 diopters: a randomized study. *Ophthalmology* 2002; 109:955– 64.
- Stulting RD, John ME, Maloney RK, Assil KK, Arrowsmith PN, Thompson VM. Three-year results of Artisan/Verisyse phakic intraocular lens implantation. Results of the United States Food And Drug Administration clinical trial. *Ophthalmology* 115(3), 464–472.e1 (2008).
- Maloney RK, Nguyen LH, John ME. Artisan phakic intraocular lens for myopia: short-term results of a

- prospective, multicenter study. *Ophthalmology* 109(9), 1631–1641 (2002).
11. Tahzib NG, Nuijts RM, Wu WY, Budo CJ. Long-term study of Artisan phakic intraocular lens implantation for the correction of moderate to high myopia: ten-year follow-up results. *Ophthalmology* 114(6), 1133–1142 (2007).
  12. Budo C, Hessloehl JC, Izak M *et al.* Multicenter study of the Artisan phakic intraocular lens. *J. Cataract. Refract. Surg.* 26(8), 1163–1171 (2000).
  13. Silva RA, Jain A, Manche EE. Prospective long-term evaluation of the efficacy, safety, and stability of the phakic intraocular lens for high myopia. *Arch. Ophthalmol.* 126(6), 775–781 (2008)