

Original Article

EFFECT OF SNAKEHEAD FISH AND SEA CUCUMBER EXTRACT ADMINISTRATION ON MAST CELL INFILTRATION, INTERLEUKIN-6 (IL-6), AND ALBUMIN LEVELS IN BURNS AND SURGICAL WOUNDSPurwoko^{1a} , Bambang Novianto Putro¹, Arif Zuhail Amin Hananto¹¹ Department of Anesthesiology and Intensive Therapy, Universitas Sebelas Maret / Dr. Moewardi General Hospital, Surakarta, Indonesia^a Corresponding author: purwokoanest@gmail.com**ABSTRACT**

Introduction: Burn injury impairs almost every organ system, which causes significant morbidity and mortality. Meanwhile, the phases included in burn healing are inflammation, cell recruitment, matrix deposition, epithelialization, and tissue remodeling phase. Previous studies showed that snakehead fish and sea cucumber extract have these effects and are beneficial in burn and post-surgery wounds. **Objective:** This study aims to analyze the effect of snakehead fish and sea cucumber extract supplementation towards mast cell infiltration, IL-6, and albumin level in burn and post-surgery wounds. **Materials and Methods:** A double-blind randomized control trial was carried out at Dr. Moewardi Hospital Surakarta in November 2017 on 30 subjects, which were divided into 2 groups. Mast cell infiltration was observed on burn and post-surgery wounds colored with Toluidine Blue, while IL-6 and albumin were measured in blood, where both groups had comparable basic characteristics. **Results and Discussion:** There was a statistically insignificant ($p=0.835$) higher increase in albumin level in the treatment group, while an insignificant ($p=0.056$) greater decrease also occurred in the IL-6 level. The decrease in mast cell infiltration after treatment was also higher and not statistically significant ($p=0.526$). Previous studies showed that amino acids from snakehead fish play an important role in wound healing. Meanwhile, high EPA content in sea cucumber is due to its ability as an Echinodermata to regenerate tissue. It was also discovered that the results available about sea cucumber and sea snake extract on wound healing are different based on the skin condition after the use of the extracts. **Conclusion:** Snakehead fish and sea cucumber extract supplementation can increase albumin level, decrease IL-6 level and mast cell infiltration in burn or post-surgery wounds.

Keywords: Albumin; Burn; IL-6; Mast Cell Infiltration; Snakehead Fish and Sea Cucumber Extract; Wound Incision**ABSTRAK**

Pendahuluan: Luka bakar merupakan luka sangat traumatis karena melemahkan hampir setiap sistem organ sehingga menyebabkan morbiditas dan mortalitas yang signifikan. Terdapat beberapa fase dalam penyembuhan luka bakar, yaitu fase inflamasi, rekrutmen sel, deposisi matriks, epitelisasi dan remodelling jaringan. Ekstrak ikan gabus dan teripang dipikirkan dapat mencapai efek-efek tersebut sehingga menguntungkan bagi penyembuhan pasien luka bakar dan luka operasi. **Tujuan:** Peneliti menulis penelitian ini untuk menganalisis pengaruh pemberian ekstrak ikan gabus dan teripang terhadap infiltrasi sel mast, kadar IL-6, dan albumin darah pasien luka bakar atau luka pasca operasi. **Bahan dan Metode:** Penelitian dengan desain double blind randomized control trial dilakukan di RS Dr. Moewardi Surakarta pada 30 subjek, dimulai pada bulan November 2017. Subjek dibagi ke dalam dua kelompok. Infiltrasi sel mast diamati pada kerokan luka bakar atau luka operasi yang diwarnai dengan Toluidine Blue, sedangkan kadar IL-6 dan albumin diukur dari darah pasien. Kedua kelompok memiliki karakteristik dasar yang homogen. **Hasil dan Pembahasan:** Terjadi peningkatan kadar albumin yang lebih tinggi pada kelompok perlakuan, namun tidak bermakna secara statistik ($p=0,835$). Selain itu, terjadi penurunan kadar IL-6 yang lebih besar pada kelompok perlakuan meskipun tidak bermakna secara statistik ($p=0,056$). Demikian juga penurunan infiltrasi sel mast sesudah perlakuan lebih tinggi pada kelompok perlakuan, namun tidak bermakna secara statistik ($p=0,526$). **Kesimpulan:** Pemberian ekstrak ikan gabus dan teripang meningkatkan kadar albumin dan menurunkan kadar IL-6 dan infiltrasi sel mast pada pasien luka bakar atau luka operasi.

Kata Kunci: Albumin; Luka Bakar; IL-6; Infiltrasi Sel Mast; Ekstrak Ikan Gabus dan Teripang; Luka Operasi

Article info: Received May 18th 2021, Received in revised form July 2nd 2021, Accepted November 9th 2021

INTRODUCTION

Wound healing is a complicated process, which consists of 3 phases, namely inflammation, proliferation, and maturation. The inflammation phase is preceded by hemostasis and inflammation that lasts for at least 7 days. Meanwhile, the proliferation phase is marked with epithelization, angiogenesis, granulation formation, and collagen deposition, which starts at least 3 days after injury and lasts for approximately 7 days. The maturation phase has transitional characteristics from granulation tissue into scar formation. This phase starts from the 7th day and may last for several weeks (1). During normal wound healing, the monocyte changes into macrophage after infiltration, while at the end of the inflammation phase, the inflammation signal subsides and finally stops. This is important because prolonged inflammation causes chronic wound healing. Therefore, reducing the production or release of NO, PGE₂, and other cytokines such as TNF- α , IL-1 β , IL-6, and COX-2 is a good strategy to prevent prolonged inflammation (2). In the study by Zohdi RM et al, rats with burn injury were treated with sea cucumber-based hydrogel and showed significant wound healing. It had lower levels of IL-1 α , IL-1 β , and IL-6 compared to the control group. Meanwhile, lower pro-inflammatory cytokines make better wound healing (3). According to Ab Wahab SZ et al, wound healing in cesarean section patients treated with snakehead fish extract gave significant results. This was due to higher amino acids such as glycine and fatty acids such as arachidonic acid, which are involved in wound healing through collagen re-modeling and wound re-epithelialization mechanism (4).

Treatment using snakehead fish and sea cucumber extract in burn and post-surgery wounds is assumed to reduce the inflammation process, help in re-modeling and re-epithelialization, as well as quicken wound healing. In addition, they are also assumed to increase the albumin levels.

MATERIALS AND METHODS

This study was conducted from March to July 2018 in the Central Surgery Installation and inpatient care of Dr. Moewardi Hospital, Surakarta, after the ethics committee acceptance. It was a double-blind randomized controlled trial with 35 subjects, where 5 were dropped out (3 had nausea and vomiting, while the other 2 had deteriorating conditions). After randomization, a total of 15 subjects were treated with snakehead fish and sea cucumber extract, while the other 15 were treated with placebo. Inclusion criteria were 18-65 years old male or female subjects with burn injury or post-surgery wound, have received treatment in inpatient care, High Care Unit, or Intensive Care Unit, burned surface area of 10-50% or post-laparotomy wound, and consented to be the subjects of the study. Exclusion criteria were allergy to snakehead fish and sea cucumber extract, electrical burn injury, severe liver disease such as cirrhosis, and malignancy. Drop-out criteria were deteriorating condition and death.

RESULTS AND DISCUSSION

Based on Table 1, the characteristics of patients with burn injury and post laparotomy are insignificantly different, which showed that their characteristics are homogenous.



Table 1. Characteristics of Study Subjects

Characteristics	Group		p-value
	K1	K2	
Sex ^b			0.269
Male	5(33.3%)	8(53.3%)	
Female	10 (66.7%)	7 (46.7%)	
Age ^a	44.13±11.50	41.47±13.79	0.57
Weight ^a	56.47±8.54	51.87±5.41	0.089
Height ^a	164.40±3.60	164.73±3.92	0.81
BMI ^c			0.282
Underweight	5 (33.3%)	7 (46.7%)	
Normal	8 (53.3%)	8 (53.3%)	
Overweight	2 (13.3%)	0 (0.0%)	

^a independent sample T-test (unpaired, normal distribution)

^b Chi-square test (unpaired, nominal data)

^c Mann Whitney test (unpaired, ordinal data)

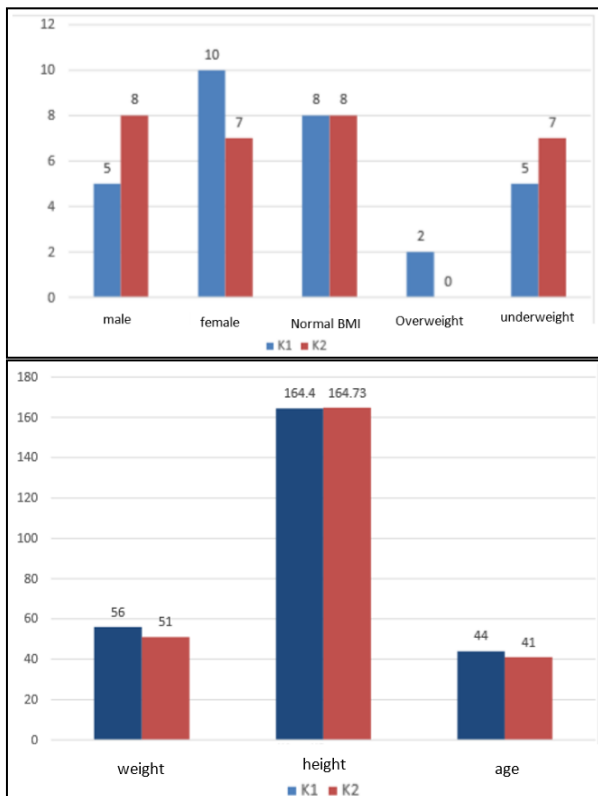


Figure 1. Characteristics of Study Subjects

From Table 2, the difference between albumin level before and after treatment (pre-test and post-test) are better than the control group with a p-value of 0.835 ($p > 0.05$). Meanwhile, this value showed that the difference is not significant.

Table 2. The Difference on Albumin Level in Snakehead Fish and Sea Cucumber Extract Treatment Compared to Control Group

Group	Albumin			p-value
	Pre-test	Post-test	Δ	
Group 1	2.87±0.56	2.97±0.47	0.10±0.36	0.298 ^c
Group 2	2.77±0.53	2.99±0.45	0.22±0.49	0.103 ^c
p-value	0.618 ^a	0.906 ^a	0.835 ^b	

^a independent sample T-test (unpaired, normal distribution)

^b Mann Whitney (unpaired, abnormal distribution)

^c paired sample T-test (paired, normal distribution)

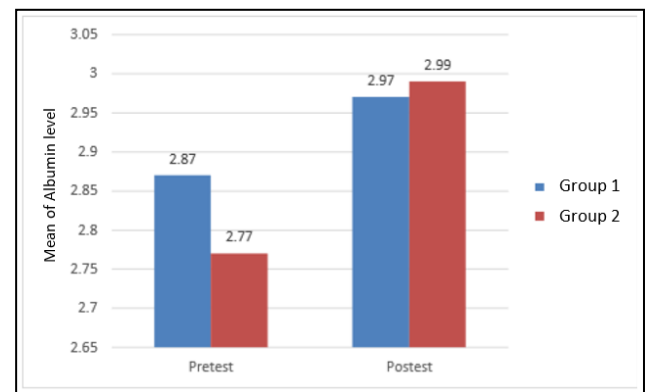


Figure 2. The Difference on Albumin Level in Snakehead Fish and Sea Cucumber Extract Treatment Compared to Control Group

Table 3. The Difference on IL-6 Level in Snakehead Fish and Sea Cucumber Extract Treatment Compared to Control Group

Group	IL-6			p-value
	Pre-test	Post-test	Δ	
Group 1	249.78 ±170.93	171.7 ±136.27	-78.09 ±160.08	0.027 ^d
Group 2	400.24 ±163.35	204.59 ±148.65	-195.65 ±162.51	<0.001 ^c
p-value	0.020 ^a	0.443 ^b	0.056 ^a	

^a Independent sample T-test (unpaired, normal distribution)

^b Mann Whitney (unpaired, abnormal distribution)

^c Paired sample T-test (paired, normal distribution)

^d Wilcoxon test (paired, abnormal distribution)

From Table 3, the treatment group has a greater decrease of IL-6 level compared to the control group, however, it is statistically insignificant.

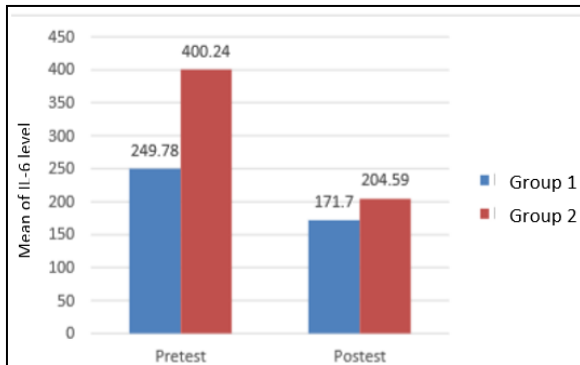


Figure 3. The Difference on IL-6 Level in Snakehead Fish and Sea Cucumber Extract Treatment Compared to Control Group

Based on Table 4, there was a statistically insignificant difference in the treatment group with a greater decrease of mast cell infiltration compared to the control group.

Table 4. The Difference on Mast Cell Infiltration in Snakehead Fish and Sea Cucumber Extract Treatment Compared to Control Group

Group	IL-6			p-value
	Pretest	Posttest	Δ	
Group 1	12.53 \pm 6.08	10.60 \pm 7.15	-1.93 \pm 10.19	0.474 ^d
Group 2	16.80 \pm 8.79	12.40 \pm 7.03	-4.40 \pm 10.82	0.138 ^c
p-value	0.133 ^a	0.493 ^b	0.526 ^a	

^a independent sample T-test (unpaired, normal distribution)

^b paired sample T-test (paired, normal distribution)

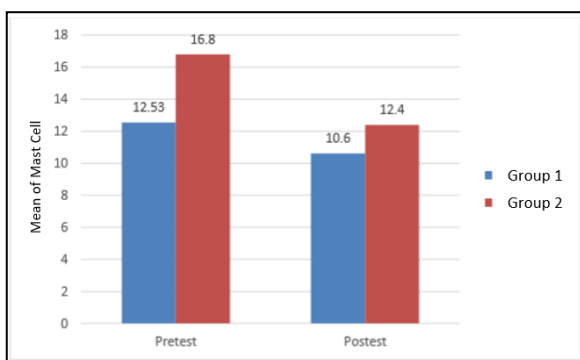


Figure 4. The Difference on Mast Cell Infiltration in Snakehead Fish and Sea Cucumber Extract Treatment Compared to Control Group

Previous studies showed that amino acids such as glycine, glutamine, and arginine from snakehead fish play important role in wound healing. Although the capsules of albumin

from snakehead fish extract are effective in increasing albumin level and reducing pitting edema, they do not affect the length of stay in patients with severe preeclampsia who passed through cesarean section (5). This is different from sea cucumber (*Stichopus chloronatus*), which contained fatty acids such as arachidonic acid, eicosapentaenoic acid (EPA), and docosahexaenoic acid (DHA) that are potentially used in tissue repair and wound healing. Similarly, high EPA content in sea cucumber is based on its ability as an Echinodermata to regenerate tissue. Most of its wall protein, approximately 70% consists of collagen, which is an important component for connecting tissue (6).

The study by Siti Zubaidah Ab Wahab et al. on the treatment of post-Caesarian section patients using *Channa striatus* extract compared to placebo gave an insignificant ($p < 0.511$) result after 3 days and also ($p < 0.538$) after 6 weeks post-surgery (4). These were different from the results of Zohdi RM et al., where rats with burn injury were treated with topical sea cucumber hydrogel, and their levels of pro-inflammatory cytokine (IL-1 α , IL-1 β , and IL-6) were reduced significantly on the 7th day (3). Yamanaka H et al. also examined the effect of Collagen Peptide (nutritional drink with 10 g of collagen) treatment on pressure ulcer healing compared to the control group. The results were significant in wound evaluation such as depth, granulation, exudate, size, inflammation/infection, necrotic tissue, albumin level, pre-albumin, and other parameters in the treatment group compared to the control after 4 weeks. Meanwhile, a recommended guideline published by the Japanese Society of Pressure Ulcer on the prevention and management of ulcer pressure with collagen peptide for supplemental nutrition is currently at level C1 due to limited data (7).

The study by Proksch E et al. on skin elasticity after oral collagen supplementation for 4 weeks compared to the control group showed that patients with 2.5 g and 5 g of collagen supplementation had better skin elasticity (7). Koyama Y also published a few clinical studies on the effect of supplemental collagen peptide (CP) in Japanese. Based on the results of the double-blind controlled trial using a placebo, it was discovered that daily consumption of 5 g CP increased the elasticity of face skin and reduced ultraviolet-induced skin erythema. There was also an increase in T cell-related immunity in Japanese with chronic fatigue after 10 g of CP daily for 8 weeks (8).

CONCLUSION

Patients treated with snakehead fish and sea cucumber extracts had a greater increase in albumin level and a higher decrease in IL-6 level as well as mast cell infiltration compared to the control group. However, the results were statistically insignificant due to the short duration of treatment. In other similar studies about collagen's effect on wound healing, these extracts need to be administered for 4 weeks.

REFERENCES

1. Sinno H, Prakash S. Complements and the Wound Healing Cascade: An Updated Review. *Plast Surg Int.* 2013;2013:1-7. doi:10.1155/2013/146764
2. Dorjsembe B, Lee HJ, Kim M, Dulamjav B, Jigjid T, Nho CW. Achillea asiatica extract and its active compounds induce cutaneous wound healing. *J Ethnopharmacol.* 2017;206:306-314. doi:10.1016/j.jep.2017.06.006
3. Zohdi RM, Zakaria ZAB, Yusof N, Mustapha NM, Abdullah MNH. Sea cucumber (*Stichopus hermannii*) based hydrogel to treat burn wounds in rats. *J Biomed Mater Res - Part B Appl Biomater.* 2011;98 B(1):30-37. doi:10.1002/jbm.b.31828
4. Ab Wahab SZ, Abdul Kadir A, Nik Hussain NH, et al. The Effect of Channa striatus (Haruan) Extract on Pain and Wound Healing of Post-Lower Segment Caesarean Section Women. *Evidence-based Complement Altern Med.* 2015;2015. doi:10.1155/2015/849647
5. Chairuddin, B. 2012. Efektivitas Pemberian Kapsul Albumin Ekstrak Ikan Gabus Terhadap Kenaikan Kadar Albumin dalam Darah Pasien Preeklampsia Berat Pasca Seksio Sesarea. *Tesis ilmu biomedik*
6. Bordbar S, Anwar F, Saari N. High-value components and bioactives from sea cucumbers for functional foods - A review. *Mar Drugs.* 2011;9(10):1761-1805. doi:10.3390/md9101761
7. Yamanaka H, Okada S, Sanada H. A multicenter, randomized, controlled study of the use of nutritional supplements containing collagen peptides to facilitate the healing of pressure ulcers. *J Nutr Intermed Metab.* 2017;8:51-59. doi:10.1016/j.jnim.2017.05.001
8. Y K. Effects of Collagen Ingestion and their Biological Significance. *J Nutr Food Sci.* 2016;06(03). doi:10.4172/2155-9600.1000504

