

Orthognathic Surgery Combined with Orthodontic Treatment in a Patient with Bilateral Cleft Lip, Palate and Alveolus, Without Alveolar Bone Graft: A Case Report

Yudi Siswanto^a, Magda Rosalina Hutagalung^{a*}, Indri Lakhsmi Putri^a,
Jusuf Sjamsudin^b

^aDepartment of Plastic Reconstructive and Aesthetic Surgery, Faculty of Medicine Universitas Airlangga

^bDepartment of Orthodontics, Faculty of Dentistry Universitas Airlangga

ARTICLE INFO

ABSTRACT

Keywords:
Orthognathic
Orthodontic
Cleft Lip
Craniofacial
Reconstruction

Background: The incidence of cleft lip and palate is 8 in every 10,000 live births. A patient with this condition experiences a deficiency in maxillary growth. Maxillary hypoplasia leads to malocclusion and skeletal disharmony. Orthognathic surgery at skeletal maturity is the standard procedure at the end of the protocol to correct maxillary hypoplasia resulting in malocclusion not correctable with orthodontics alone.

Case Presentation and Operation Technique: We report the result of orthognathic surgery performed on a 23 year old male with complete bilateral cleft lip, palate, and alveolus. We proceeded with bimaxillary surgery despite the alveolar cleft. We also recorded a neglected alveolar cleft in which he should have had undergone alveolar bone graft prior to the current procedure. The pre-maxillary segment was stabilized with miniplate followed by Le Fort 1 advancement and mandibular setback guided by an occlusal wafer. Malar augmentation was done by onlay bone grafts. Mandibulo-maxillary fixation was maintained. Postoperatively, a good occlusion and better facial harmony were achieved. He was planned to undergo a septorhinoplasty in the near future.

Discussion: Despite adequate treatments following the protocol recommended by many centres, some patients developed some degree of maxillary hypoplasia. A quarter of this population need osteotomies and Le Fort I maxillary osteotomy is the most common procedure to correct retrognathic maxilla.

Conclusion: Orthognathic surgery combined with orthodontic treatment in a patient with bilateral cleft lip and palate provided good functional and aesthetic result. However, this procedure cannot replace the standard protocol of having an alveolar bone graft performed before permanent canine eruption to achieve optimal outcomes.

Cleft lip and palate is the most common congenital facial anomaly. In patients with bilateral cleft lip and palate, the posterior alveolar segments can be collapsed

medially to a greater degree, which may result in an extremely narrow maxilla with bilateral posterior cross bite. It is well documented that patients with a history of cleft lip and palate

* Corresponding author: Magda Rosalina Hutagalung - Department of Plastic Reconstructive and Aesthetic Surgery, Faculty of Medicine Universitas Airlangga
Email address: magdahutagalung@rocketgmail.com (M. R. Hutagalung)

exhibit varied degrees of maxillary hypoplasia with continued growth and development.

On the other hand, patients born with cleft lip and palate must undergo a number of corrective surgical procedures during their infancy and early childhood. The scarring that results from these procedures has been shown to affect the growth of the maxilla, often leading to maxillary deficiency.^{1,2,3} The timing and execution of initial repairs and subsequent interventions have been scrutinized and refined in an attempt to maximize the benefits while keeping minimal interference with maxillary growth.

If the growth pattern of maxilla is favourable and the alveolar bone graft is successful, orthodontic treatment is carried out in the early teens and is sufficient to idealize the occlusion.⁴ Studies reveal that a considerable percentage of patients with a history of complete cleft lip and palate require orthognathic surgery. A study in

Canada showed that roughly 65% of patients with bilateral cleft lip and palate who received their primary lip and palate repairs at early age could benefit from orthognathic surgery.⁵ Along the same lines, DeLuke et al. (1997) reported that 25% of 28 patients with mixed types of cleft lip and palate required orthognathic surgery, having followed their institution's treatment protocol.⁶ On the other hand, Rosenstein et al. (2003) stated that in their centre, where primary bone grafting is performed at the time of initial lip repair, the rate of orthognathic surgery was 18.29% in a sample of 82 patients with mixed types of cleft lip and palate.⁷ Similarly, Cohen et al. (1995) recommended orthognathic surgery to 24% of patients with bilateral cleft lip and palate.⁸ More recently, a group from Boston Children's Hospital reported frequencies of Le Fort I osteotomy of 76.5% for patients with complete cleft lip and palate.⁹

Such orthognathic surgery is commonly performed at skeletal maturity for correction of a skeletal class III malocclusion, taking a minimum age of 15 years. This was considered to be an age where one could make a reasonable

judgment as to the eventual need (or not) for orthognathic surgery due to a skeletal malrelationship.⁵ In our craniofacial division at Dr Soetomo Hospital Surabaya, orthognathic surgery is performed after stabilization of the premaxilla with alveolar bone graft at around 9 (nine) years old when two thirds of the secondary canines have developed.

We present here a case of a patient with bilateral cleft lip, palate and alveolus who underwent orthognathic surgery combined with orthodontic treatment without previous alveolar bone graft.

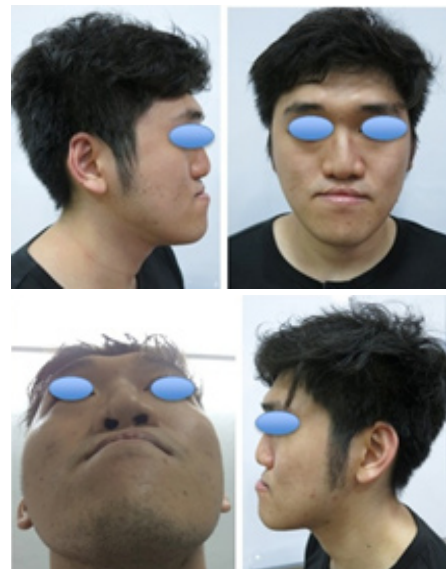

Figure 1. Pre-treatment extra-oral photographs

CASE PRESENTATION AND OPERATION TECHNIQUE

Clinical finding

An otherwise healthy 23-year-old male reported to our outpatient clinic for the correction of his facial deformity, with the chief complaint of having an under bite. Furthermore he complained of facial disproportion, hypernasal speech and fluid regurgitation from his nose with meals, and a history of bilateral cleft lip and palate. The patient had undergone cleft lip repair at the age of 3 (three) months and multiple palate repairs as a toddler and at the

age of 13 (thirteen) abroad. History of alveolar bone graft was undocumented. Nevertheless he had been on orthodontic treatment during the past 10 (ten) months until now to provide adequate jaw and dental arch relationships and establish correct position of the premaxillary segment.

On clinical examination, the patient revealed concave facial profile with a retrusive upper lip and protruded chin (retrognathic maxilla and prognathic mandible). The maxilla was smaller and located in a more posterior and upward position and both cheeks were flat. The facial proportion revealed a lower third was longer compared to the middle third. The upper lip showed whistle deformity.

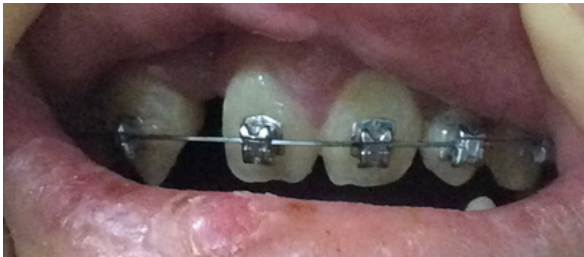

Figure 2. Pre-treatment intraoral examination

Intra-oral examination revealed a significant Angle's class III malocclusion. The upper or maxillary arch does not fit well with the mandibular arch which caused bilateral cross bite. The presence of alveolar cleft indicated negligence of alveolar bone grafting procedure. There is a persistent anterior palatal fistula and scarred palatal and buccal mucosa. The nasal septum is deviated to the right.

He was diagnosed with congenital Angle's class III malocclusion, anterior palatal fistula, velopharyngeal incompetence and bilateral cleft lip and palate post repair.

Radiographic findings

Cephalometric radiograph showed that total length of patient's midface plus lower face (N-Me) was 146 mm with mid-face length (N-ANS) of 60 mm and lower face length (ANS-Me) of 86 mm. Mid-face to lower face length ratio is 41% to 59% (normal = 45%: 55%).

According to Wendell Wylie Method, the patients sustained prognathic mandible (Angle's class III malocclusion) with prognathic and retrognathic measurement of 39.5 and 5 respectively. In accordance to Downs method, radiographic evaluation shows maxillary retrusion, mandibular prognathism, class III occlusion. CT scan reveals bilateral alveolar clefts which are practically complete, very

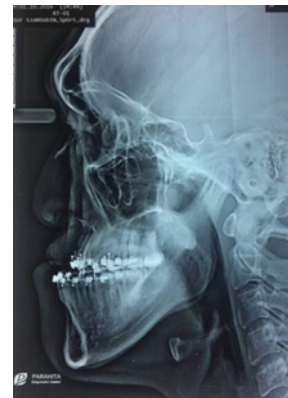

Figure 3. Pre-treatment lateral cephalometric radiograph

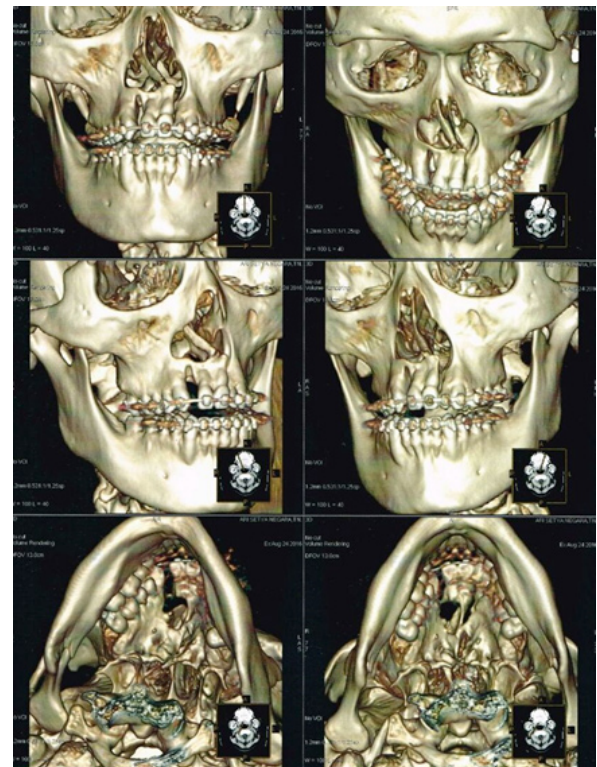


Figure 4. Pre-treatment head CT-scan

hypoplastic maxilla and septal deviation. Studies were made by the orthodontist on dental models to measure the required surgical movements and 2 splints were developed.

Reconstructive challenges

The reconstructive challenge in this patient is the correction of malocclusion. The indication for this surgery in this case is aimed at attaining good jaw function, relationship and stability, health and aesthetic. Factors contributing to the malocclusion arose from dental problems, unrepaired alveolar cleft and skeletal discrepancies; therefore treatments included orthodontics combined with orthognathic surgery.

The fact that the patient had not undergone alveolar bone graft, correction of hypoplastic and retrusive maxilla posed a great challenge. He also required correction of his midface hypoplasia.

The patient was prepared for surgery. The team caring for him was multidisciplinary involving craniofacial surgeon, orthodontist, anaesthetist, nurses, radiologist, speech therapist, ENT, etc.

Operative procedure

Under general anaesthesia and nasotracheal intubation, the patient was prepared and draped. First of all, the premaxillary segment was stabilized with a miniplate. The skeletal class III relationship was corrected by Le fort I maxillary advancement 9 mm forward and bilateral sagittal split ramus osteotomy also in order to setback the mandible 4 mm posteriorly. The new position of the jaw was accurately established by guidance of the 2 wafers. The maxillary and mandibular segments were stabilized with rigid fixation using miniplates and screws.

Malar augmentation was done by onlay bone grafts harvested from the hip. His occlusion was maintained with a mandibulo-maxillary fixation immediately after surgery.

All of these procedures were performed in one operation. For weeks after the operation,

the orthodontic treatment was continued. He was intensely followed up by the orthodontist and craniofacial surgeon. He complained of pain in the right TMJ and dysesthesia in the anterior lower jaw which subsided. A TMJ radiograph showed that the mandibular condyles were not displaced. Patient maintained a class 1 occlusion and at the end of the mandibulo-maxillary fixation and the alveolar clefts were narrowed. He showed improved facial appearance and profile and smile. The position of the upper and lower lips was normal and harmonious to each other.

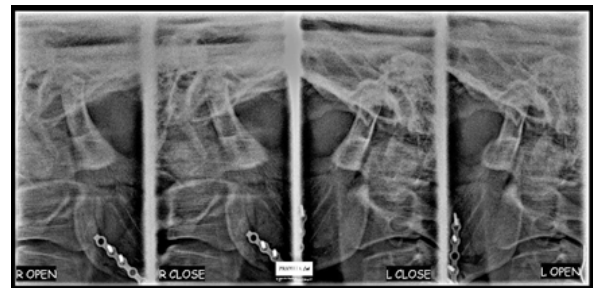


Figure 5. Post-treatment TMJ radiograph

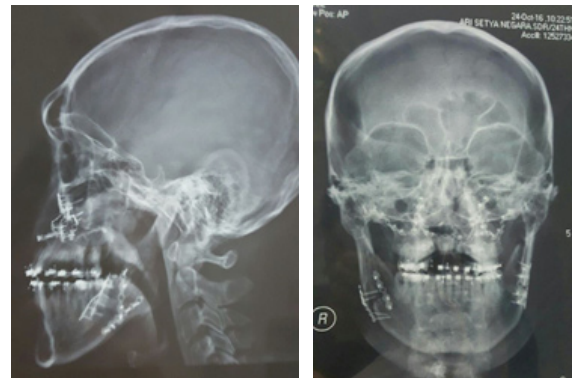

Figure 6. Post-treatment skull x-rays

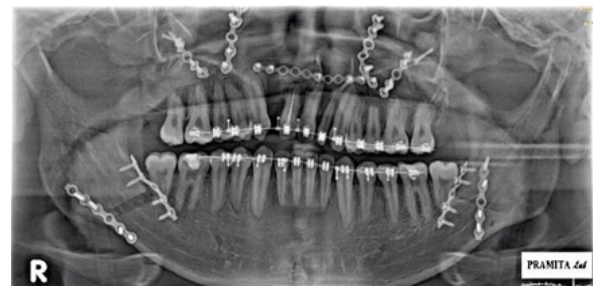

Figure 7. Post-treatment cephalogram

DISCUSSION

Malocclusion as a main problem in cleft patients may develop as a result of dental anomaly, alveolar cleft defect and skeletal disharmony between maxilla and mandible.⁽¹⁰⁾ These conditions need treatments with suitable timing. Although patients with cleft lip–cleft palate deformities have essentially normal mandibular growth, there is commonly a tendency for an anterior open bite with a steep mandibular plane angle, a decrease in posterior facial height, and an increase in anterior facial height resulting in a prognathic facial appearance.

Following cleft lip and palate repair, the patient should undergo alveolar bone graft before undergoing correction for his facial disproportion. Before alveolar bone grafting, orthodontic preparation is typically needed. Expansion of the maxilla is usually performed before alveolar bone grafting using fixed orthodontic appliances. A successful alveolar bone graft provides an alveolar ridge that is identical in height and width to the unaffected side and, if needed, can accommodate a dental implant with no additional augmentation.⁽⁴⁾

In this case, the patient did not have alveolar bone grafting prior to his current treatment which he should have received at 9 (nine) years of age when his canines were nearly fully developed, at the unfortunate time that he was not yet under our care. We decided to proceed with the orthognathic surgery without grafting the alveolar clefts considering his age and scarred buccal mucosa. Therefore, we performed a three-piece osteotomy since the patient sustained bilateral alveolar clefts and an oronasal fistula. To achieve skeletal stabilization, we performed fixation of the premaxillary segment using miniplate. Although such fixation could not provide an ideal continuity of maxillary dental arch, the final occlusion was acceptable.

Despite adequate treatments following the protocol recommended by many centres, some patients developed some degree of maxillary hypoplasia. A study by Ross showed that 25% of cleft patients necessitate maxillary osteotomy. Maxillary advancement by Le Fort I maxillary osteotomy is the most common procedure to correct retrognathic maxilla. Advancement of the maxilla is generally the preferred approach, because the midface deficiency usually affects the profile aesthetics. Some patients may require additional procedures such as bilateral sagittal split ramus osteotomy to set the mandible back if the sagittal discrepancy is too large or if there are associated mandibular issues e.g., asymmetries and canting of the mandibular occlusal plane. In our case, the occlusion had to be corrected by bimaxillary surgery because otherwise the retrognathic maxilla would have to be advanced beyond 1 cm which would worsen the velopharyngeal incompetence. Therefore correction was achieved through both Le Fort I advancement combined with mandibular setback guided by an occlusal wafer.

The patient has not shown evidence of relapse, a condition we have anticipated by limiting the maxillary advancement to less than 1 cm and by maintaining prolonged mandibulo-maxillary fixation up to 4 months which was immediately replaced with a retainer.

He is scheduled to have a pharyngoplasty and a rhinoplasty.

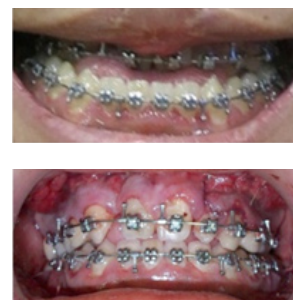

Figure 8. Pre and post-treatment intraoral photograph

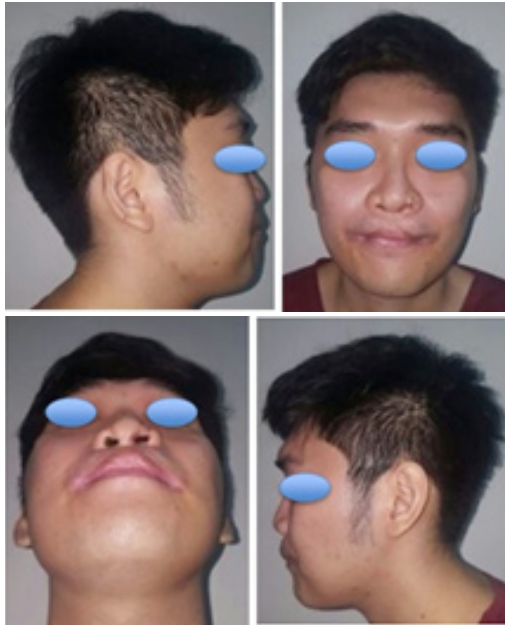

Figure 9. Four months post maxillary advancement & mandibular setback

CONCLUSION

Orthognathic surgery combined with orthodontic treatment in a patient with bilateral cleft lip and palate provided satisfying and stable outcome. Since this patient had not undergone

alveolar bone graft, the premaxillary segment was stabilized with a miniplate. However, this procedure cannot replace the standard protocol of having an alveolar bone graft performed before permanent canine eruption to achieve optimal outcomes. Nevertheless, the final result shows good functional and aesthetic result.

REFERENCES

1. Ross RB. Treatment variables affecting facial growth in complete unilateral cleft lip and palate. Part 1: treatment affecting growth. *Cleft Palate J.* 1987A; 24:5-23.
2. Mars M, Plint DA, Houston WJB, Bergland O, Semb G. The Goslon Yardstick: a new system of assessing dental arch relationships in children with unilateral clefts of the lip and palate. *Br J Plast Surg.* 1987;24:314-322.
3. Capelozza Filho L, Normando AD, da Silva Filho OG. Isolated influences of lip and palate surgery on facial growth: comparison of operated and unoperated male adults with UCL/P. *Cleft Palate Craniofac J.* 1996; 33:51-56.
4. Phillips JH, Nish I, Daskalogiannakis J. Orthognathic Surgery in Cleft Patients. *Journal of Plastic and Reconstructive Surgery.* 2012;129:535-548.
5. Daskalogiannakis J, Mehta M. The Need for Orthognathic Surgery in Patients With Repaired Complete Unilateral and Complete Bilateral Cleft Lip and Palate. *Journal of CLP and Orthognathic Surgery.* 2009;46:498-502.