

Surgical Technique for Complex Syndactyly in Apert Syndrome : A Serial Case

Williams Imanuel Mesang^a, Agus Santoso Budi^{a*}, Magda Rosalina Hutagalung^{a*}

^aDepartment of Plastic Reconstructive and Aesthetic Surgery, Faculty of Medicine Universitas Airlangga

*Corresponding author: Agus Santoso Budi - Department of Plastic Reconstructive and Aesthetic Surgery, Faculty of Medicine Universitas Airlangga. Email address : agus_sbeyk@yahoo.com

ARTICLE INFO

ABSTRACT

Keywords:
Syndactyly
Apert syndrome

Abstract: Complex syndactyly in Apert syndrome, especially complicated with synonychia and synostosis, is a surgical challenge. The incidence of Apert Syndrome is reported to be approximately 1 per 100.000 to 160.000 live births and its incidence in Indonesia is not yet known. It is practically symmetrical causing significant dysfunction and infection if not treated properly. The goals in the treatment are separation of independent digits without disturbing function and growth, creation of a lined commissure, provision of skin cover for the denuded nail edge and exposed bone, and to create aesthetically pleasing individual fingertips with proper nails, nail folds and adequate pulp fullness. Many variations of surgical release of the first web space and of the remaining syndactyly have been described. Various approaches to the bony deformity of the thumb have also been described. All previously described techniques advocate releasing a single side of a digit at any given surgery to maintain the vascularity of that digit. This is due to the unreliability of the vascular branching pattern to the digits. In this serial case, we reported 5 cases of Apert syndrome. We described the clinical findings, incision design, immediate and post-surgery follow ups. The results were uneventful, with satisfying function and aesthetic appearance.

Apert syndrome is classified as type 1 Acrocephalosyndactyly is among the 5 types of acrocephalosyndactyly in craniosynostosis syndrome.¹ The first report was by Wheaton in 1894 and a French Paediatrician, Eugene Apert, and published a series of nine cases in 1906.⁴ It is a congenital disorder characterized by craniostenosis,

exorbitism, midface hypoplasia and symmetrical syndactyly of hand and feet.¹⁻⁷ Syndactyly in Apert Syndrome is a complex anomaly of the bones, nerves, joints and the tendons.¹ It is commonly classified into 3 types that corresponds with the severity, the

first type consists of a complex (osseous and soft-tissue) syndactyly of digits 2 through 5, with the thumb largely free. This is described as the obstetrician's or spade hand.^{1,2,6} The second type involves a complex syndactyly of digits 2 through 5 with an associated simple syndactyly of the thumb. It is also known as the spoon or mitten hand.^{1-4,5} And the last

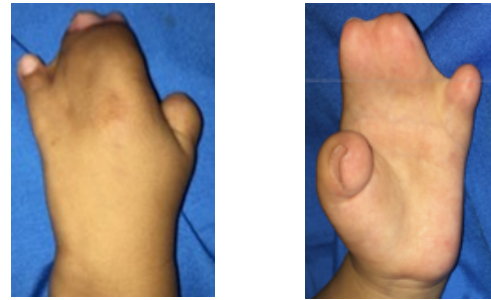type consists of complex syndactyly of digits 1 through 5, with complex syndactyly of the thumb. This type is type III (rosebud or hoof hand) that presents as a cup like hand. The functional prognosis of this type is uncertain.^{1,2,6}

In this serial case, we report 5 cases with complex syndactily in Apert Syndrome and describe each case regarding its clinical findings and surgical management.

Case Report

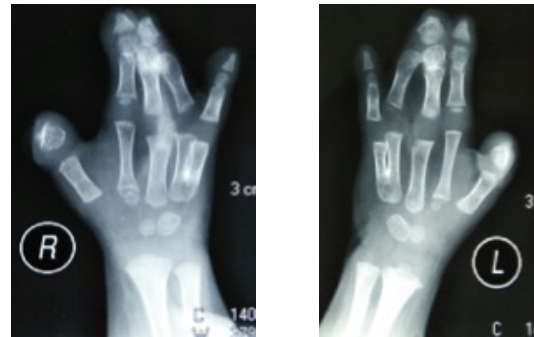Case 1

A two-year-old female diagnosed with Apert syndrome had type 1 syndactily without any nail infection (Fig. 1). The radiograph showed the bony of index-long-ring digits are joined in both hands (Fig. 2.). It was decided to do staged syndactily release to avoid vascular compromise, prioritizing release of the index fingers. For the second web space the incision design was for a dorsal rectangular flap and a V-shaped palmar flap. To reconstruct the tips of the distal phalanges, buck-gramcko pulp flap design was made to recreate the nail fold (Fig. 3). The shared nails were divided and the united distal phalanges were separated by osteotomy. Remaining defects were covered with full thickness skin graft (FTSG) absorbable 5-0 suture was used to merge the skin (Fig. 4). Pressure dressing and bandage and hand splints were used to immobilize the graft. On the 10th post-operative day, the outcome was assessed showing uneventful healing (Fig. 5).



B

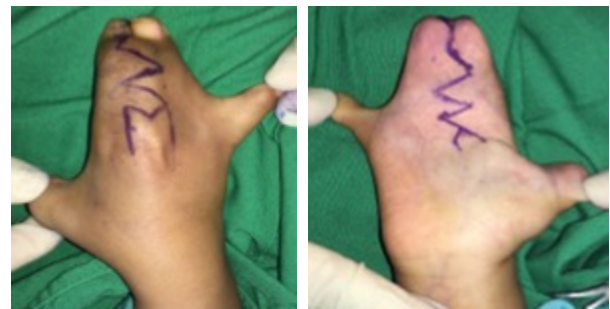Figure 1. Presurgery photo of Type 1 syndactily or spade hand, A Right hand. B Left Hand



A

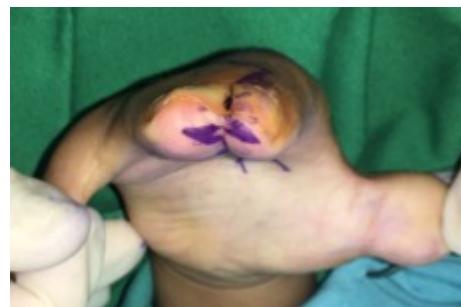B

Figure 2. X-rays of right and left hands showing the extent of bony fusion



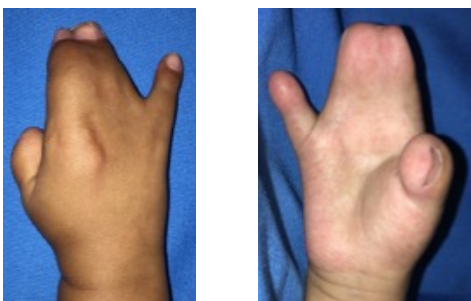A

B

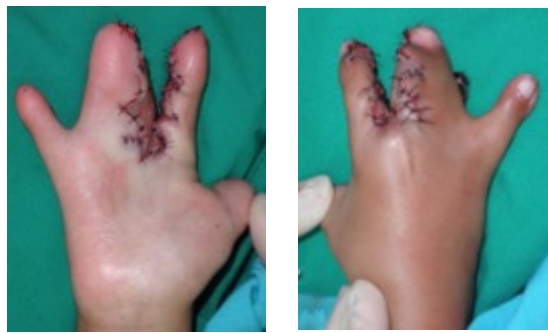

C

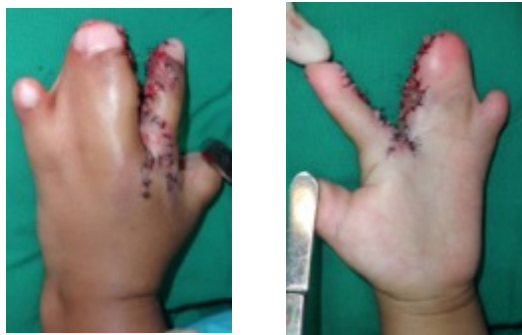Figure 3. A. Dorsal incision outline with a proximally based dorsal flap. B. Palmar incision outline. C. Buck-gramcko pulp flap design



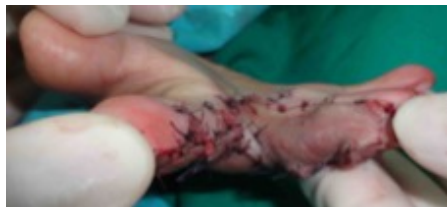A



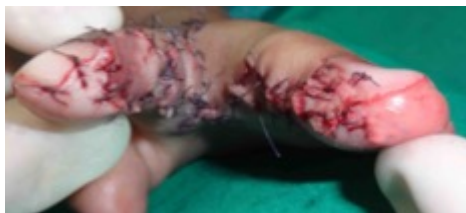A



B

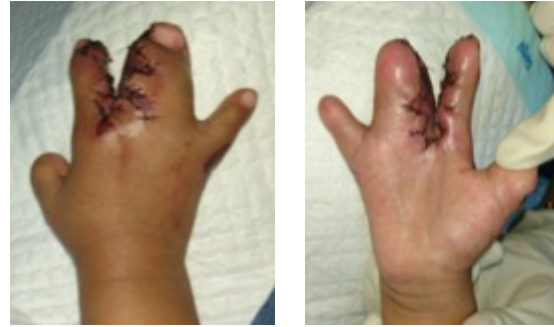

C

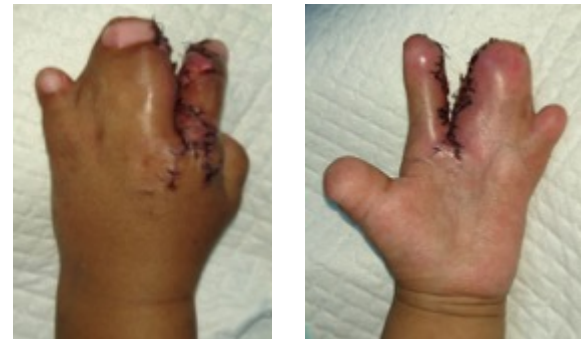
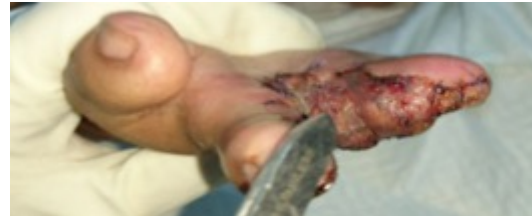
D

Figure 4. Immediate post-op photos, A. Right hand B. Left hand C. The new webspace and FTSG coverage right hand D. The new webspace and FTSG coverage left hand



A



B

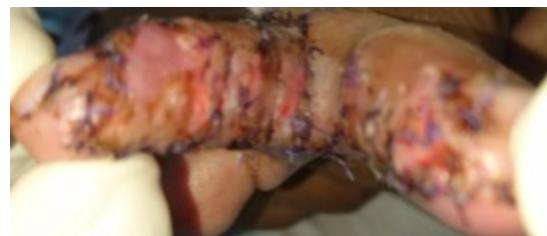

Figure 5. Follow up 10 days after surgery A. Right hand. B. Left hand.

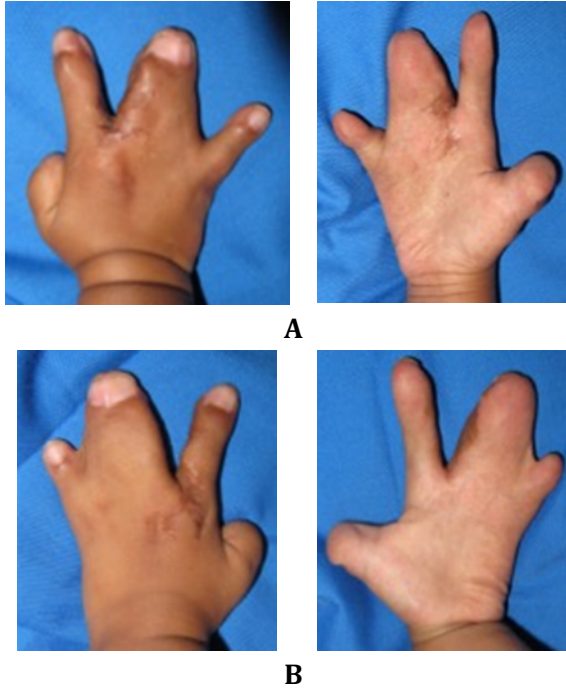


Figure 6. Follow up 6 months after surgery

Case 2

Female 19 months old presented with type 2 syndactyly or mitten hand. (Fig. 7). Hand imaging showed bony union of the index-long-ring-little digits from the distal through the proximal phalanges and simple syndactyly of the first webspace(Fig. 8). It was decided to first release the first web space bilaterally, and at the same time to also release. The second web space on the left hand (Fig. 9). Absorbable 5-0 suture was used. (Fig.10) Follow-ups to the 4th month after surgery showed uneventful healing. (Fig. 11).

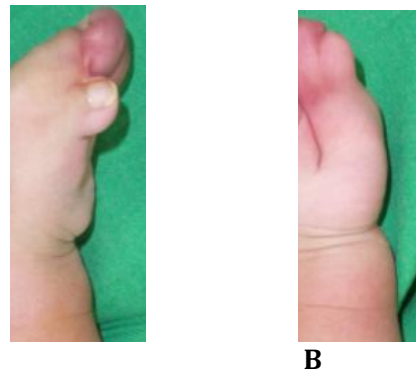
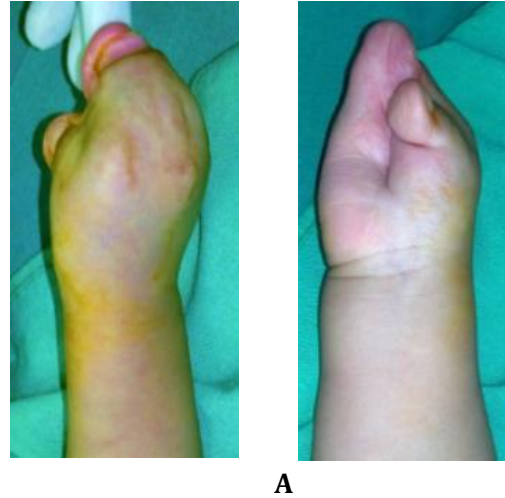


Figure 7. Pre-surgery photo of Type 2 syndactyly. A Right hand B. Left hand

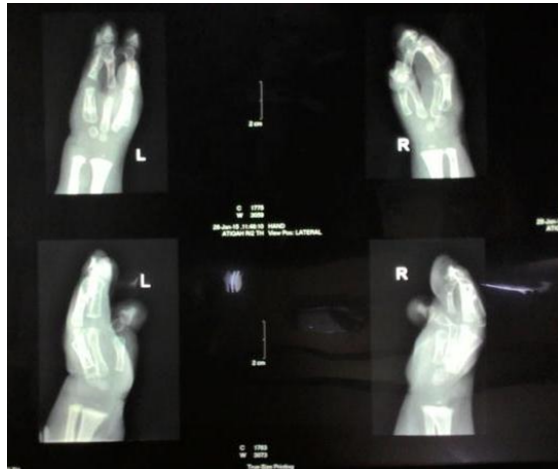

Figure 8. Pre-surgery hand radiograph of both hands showing the extent of bony fusion

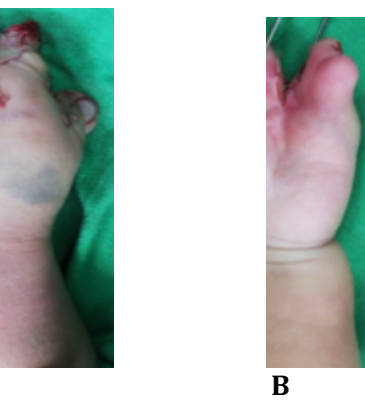
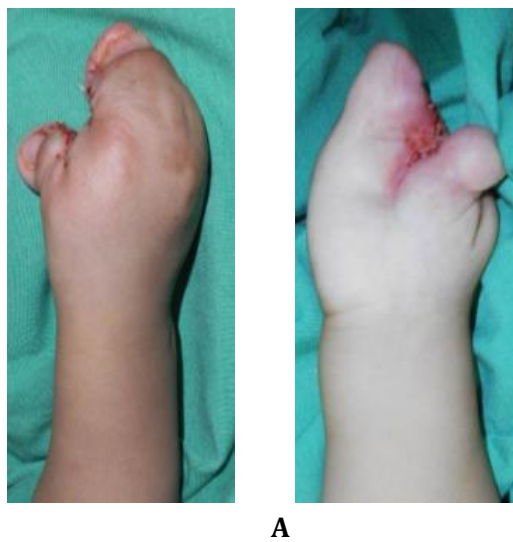


Figure 9. Intraoperative photos A. Right hand B. Left hand

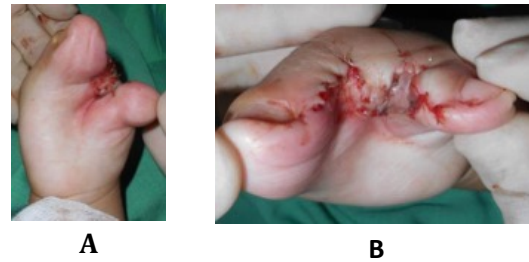


Figure 10. Post-surgery photos A. Right hand B. Left hand

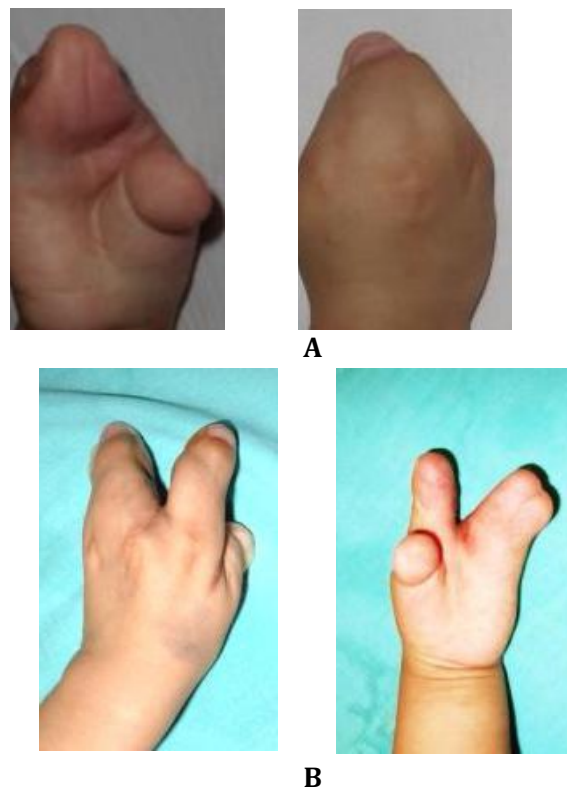
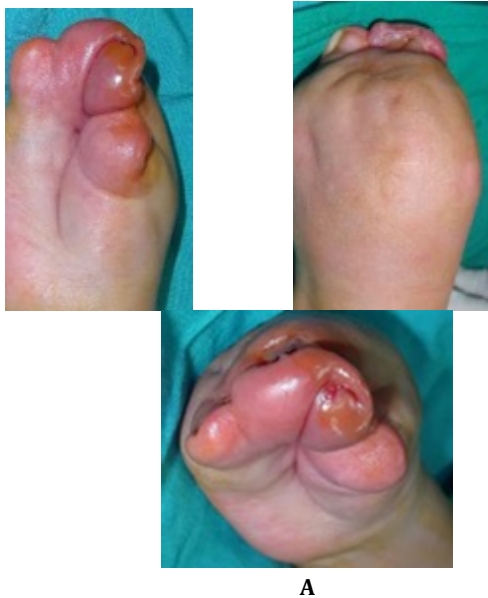

Figure 11. Follow up 4 months after surgery

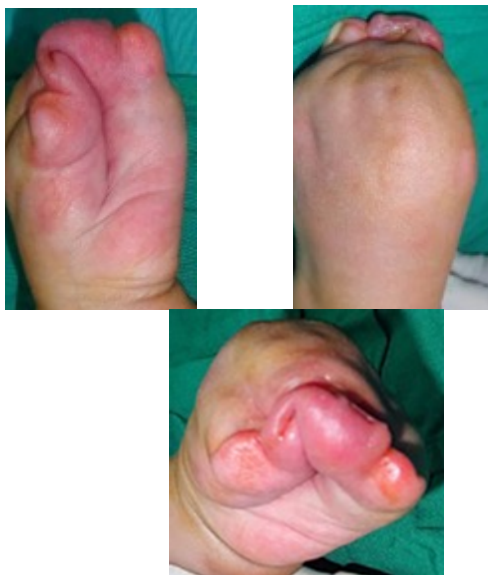Case 3

Male, 2 years old, presented with type 3 syndactyly or rose bud hand (Fig. 12). Hand x-ray showed the bones of thumb-index-long-ring-little digits are joined at the distal, middle and proximal phalanges. (Fig. 13) Multiple V-shaped interdigital flaps and Buck-gramcko pulp flaps were also used on this

patient. (Fig.14) In the first stage, the thumbs were separated and re-aligned then the first web spaces were reconstructed. Follow up at 7 days after surgery showed no vascular compromise of the flaps. (Fig.15).

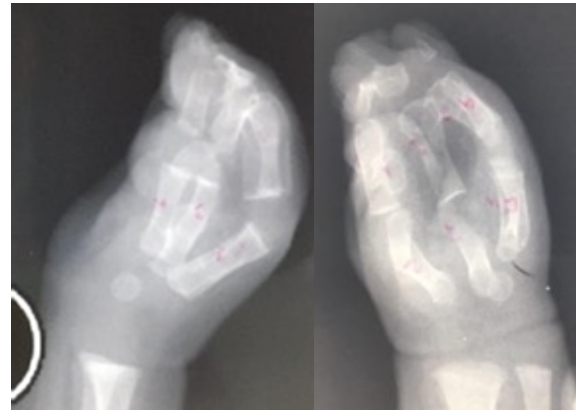

A

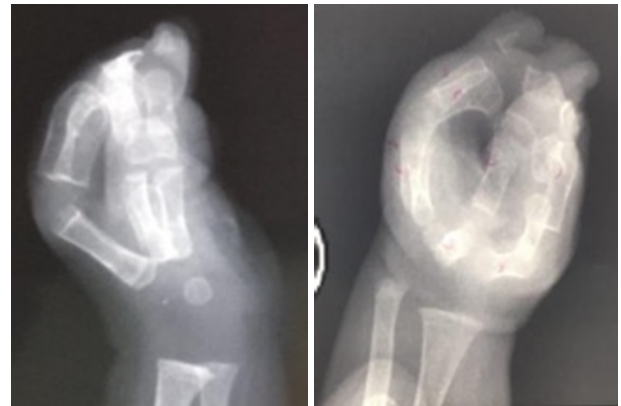

B

Figure 12. Type 3 syndactyly before surgery, A. Right Hand, B. Left hand

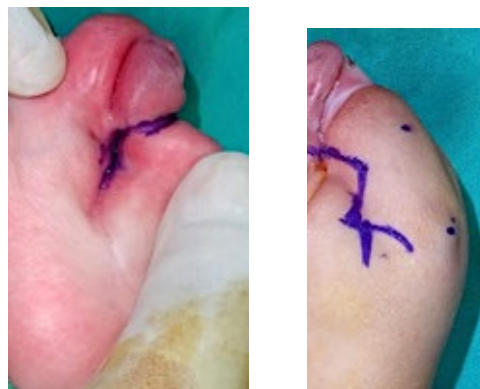

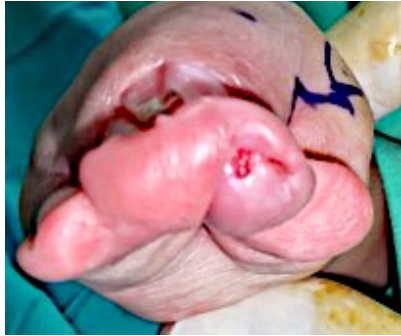A



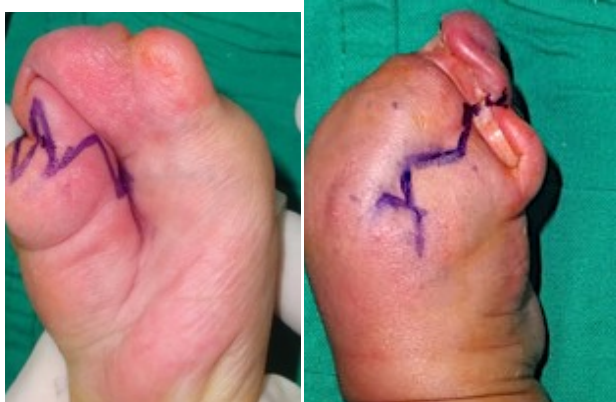B

Figure 13. Hand X-ray before thumb release, showing the extent of bony fusion



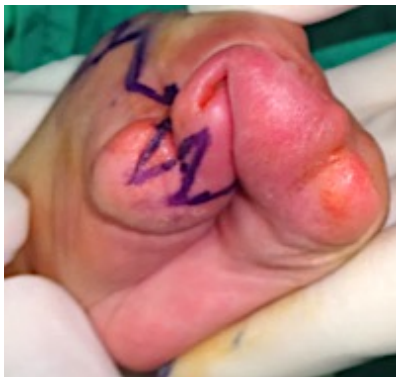

A

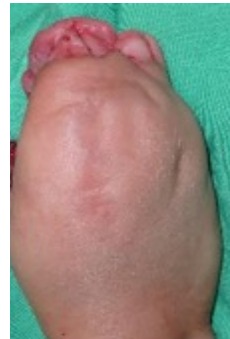


B

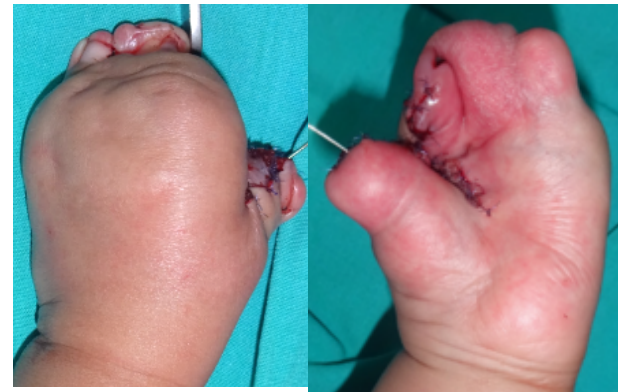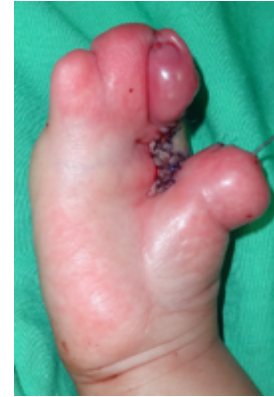Figure 14. Surgical Design to release thumb A. Right hand B. Left hand



A



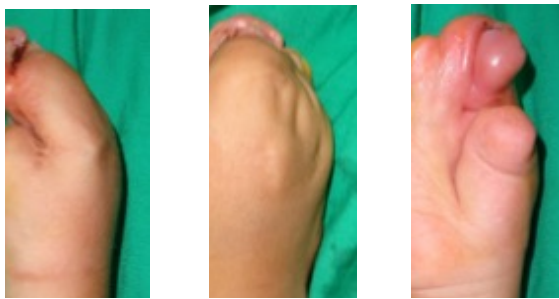A



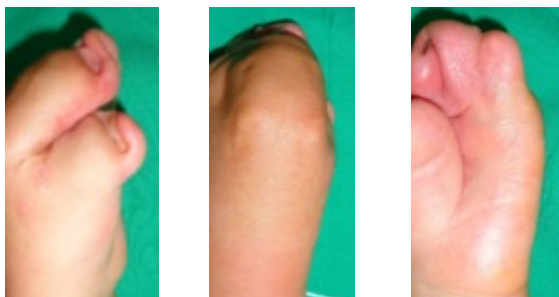
B

Figure 15. 7 days after first surgery A. Right hand B. Left Hand

In the second stage (7 months later) the third web spaces were reconstructed after the third and fourth digits were separated (Fig 16). The hand X-rays after the 1st operation is are shown (Fig 17). Proximally based dorsal rectangular flaps and V-shaped palmar flaps were used to reconstruct the third web spaces and these extend from the metacarpal heads to two-thirds the length of the proximal phalanges. A zigzag incision to form interdigital flaps is then used to separate the digits. Another zigzag incision mirroring the dorsal incision was done on the palmar side. The nail fold was created using Buck-Gramcko pulp flap. (Fig 18). Full-thickness skin graft were used to cover the remaining defects. (Fig. 19). Photos 5 days after the surgery showed no complications (Fig. 20).

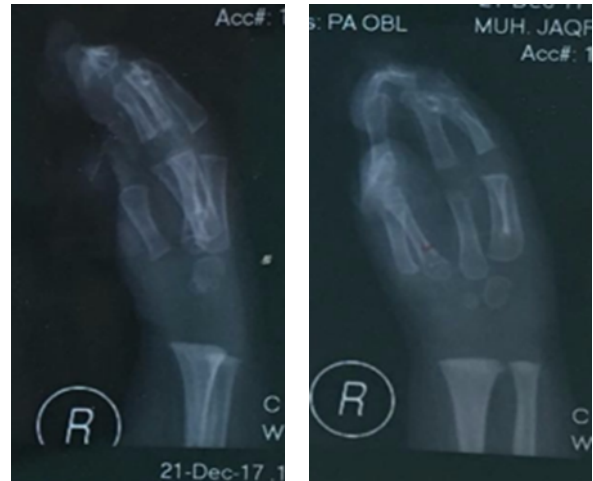
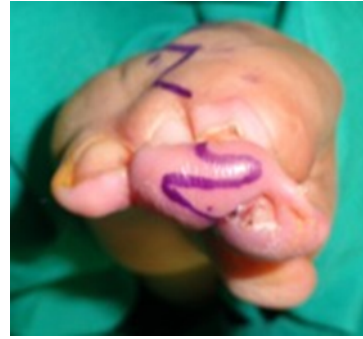
A

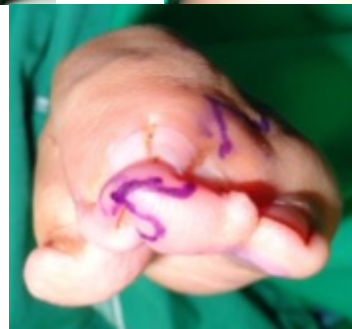
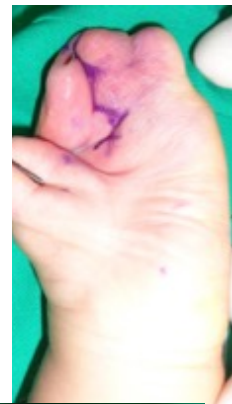
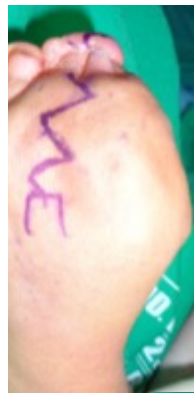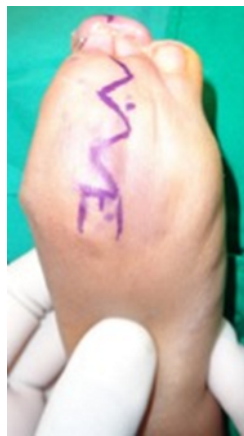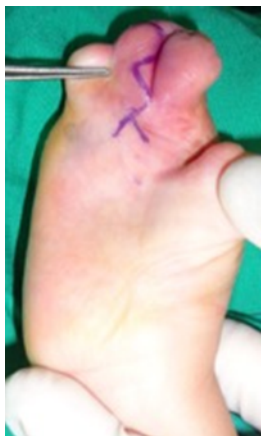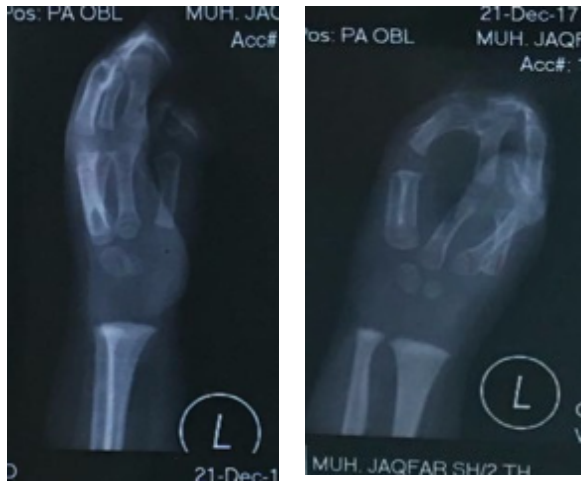B

Figure 16. Before 2nd surgery A. Right hand B. Left Hand



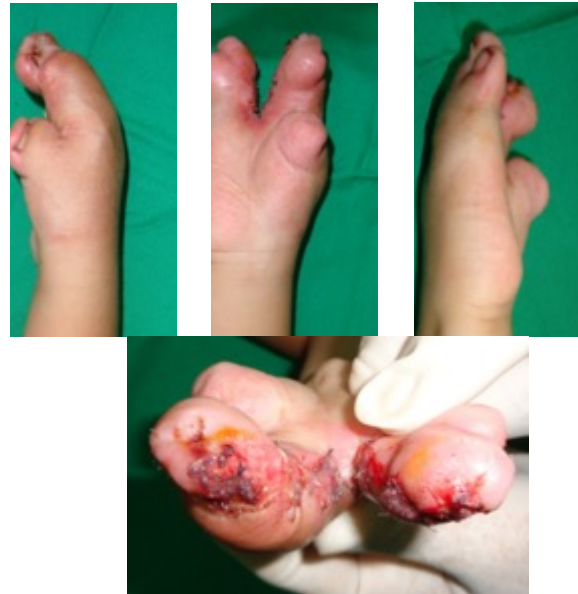A





B

Figure 17. Pre 2nd surgery hand radiograph of both hand showing the extent of bony fusion of the A. Right hand B. Left hand



A

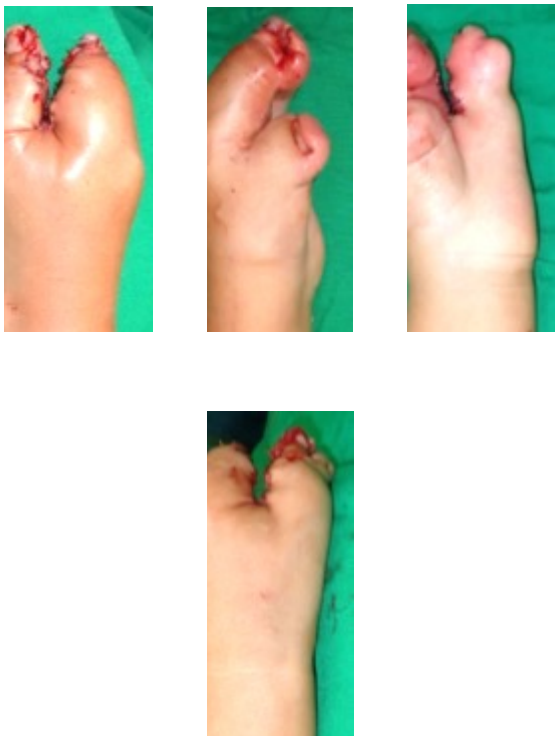
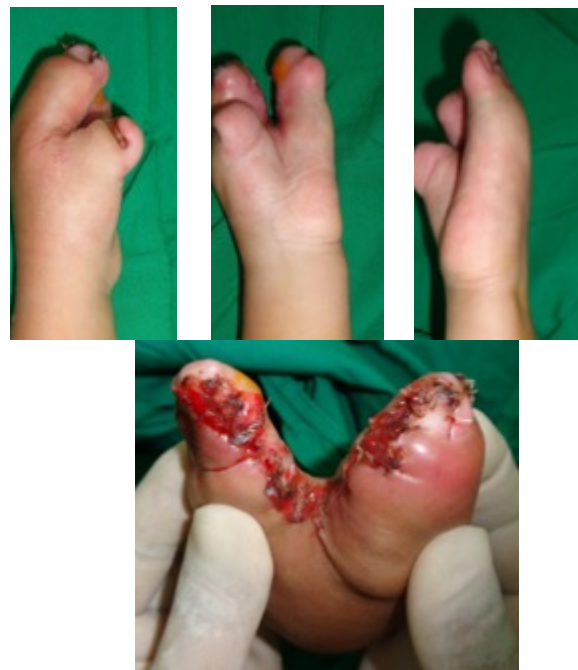
Figure 19. Immediate post-op photos A. Right hand B. Left hand



B

Figure 20. Follow up 5th days after surgery A. Right hand B. Left hand

Case 4

Male 4 years old diagnosed with Apert syndrome had type 3 syndactyly or rose bud hand (Fig. 21). Hand X-rays shows the thumb-index-long-ring-little digits are joined at both hands (Fig. 22.). Dorsal palmar flap and Zigzag incision was design to use in this patient to release the thumb, remaining the defects were covered with full thickness skin graft FTSG. (Fig. 23)

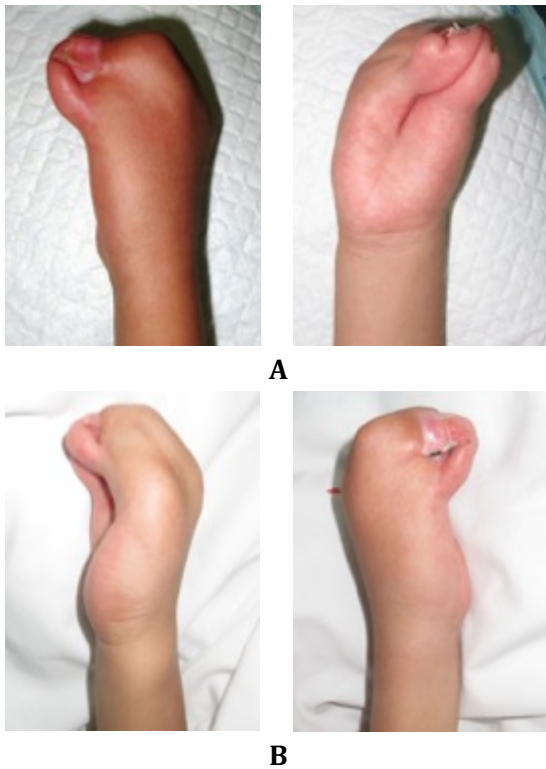


Figure 21. Clinical finding A. Right hand B. Left hand

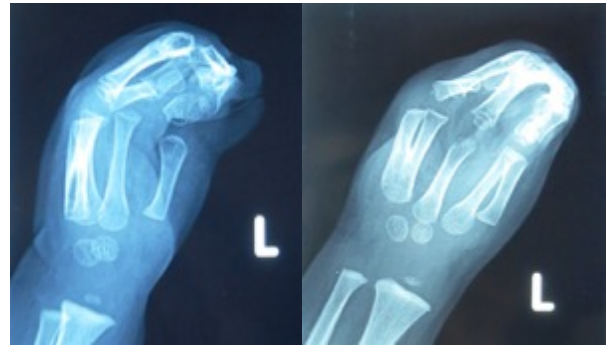
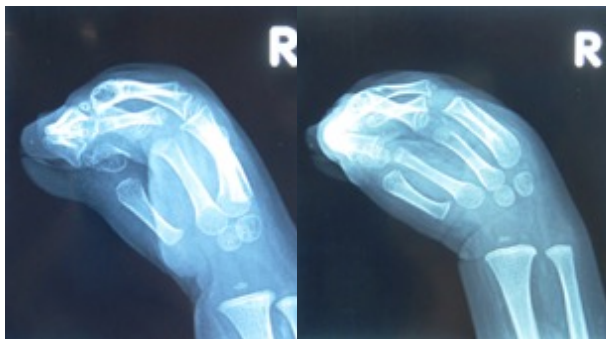
Figure 22. X-ray of both hand showing the extent of bony fusion

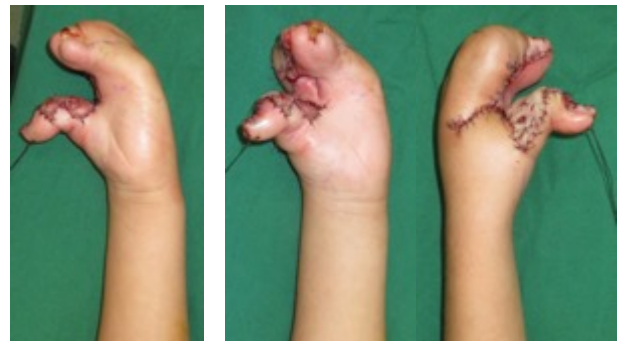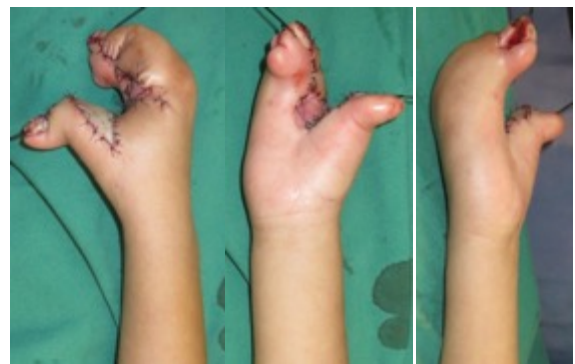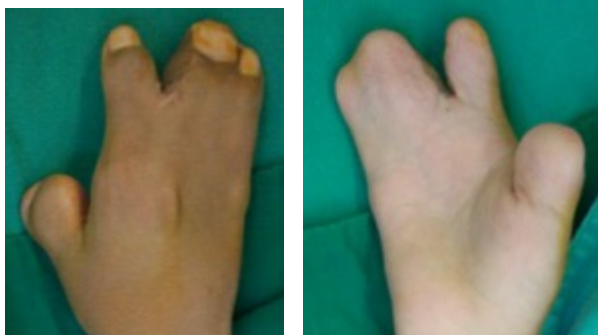


Figure 23. Early after surgery photos A. Right hand B. Left hand

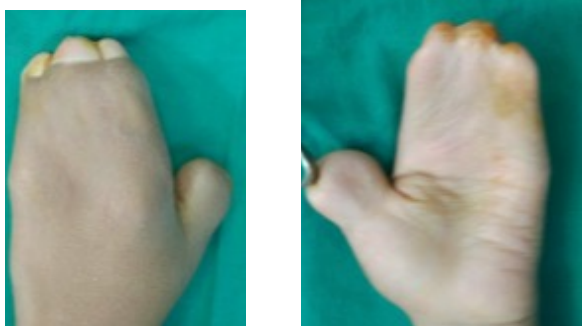
Case 5

Male 6 years old presented with Apert syndrome and first type syndactyly or spade hand (Fig. 24). X-ray showing the fusion distal phalanx of long-ring digits on the right hand and long-ring-little digits on left hand (Fig. 25). This patient was also treated using dorsal rectangular flap and a V-shaped palmar. A zigzag incision is used to separate the web of the digits on dorsal and palmar is mirroring

from the dorsal. We performed two web release at the right hand (2nd and 4th web) and 3rd web release on the left hand. (Fig. 26) During the surgery the both hand has no significant complication.



A



B

Figure 24. Type 1 syndactyly . A Right hand
B left hand

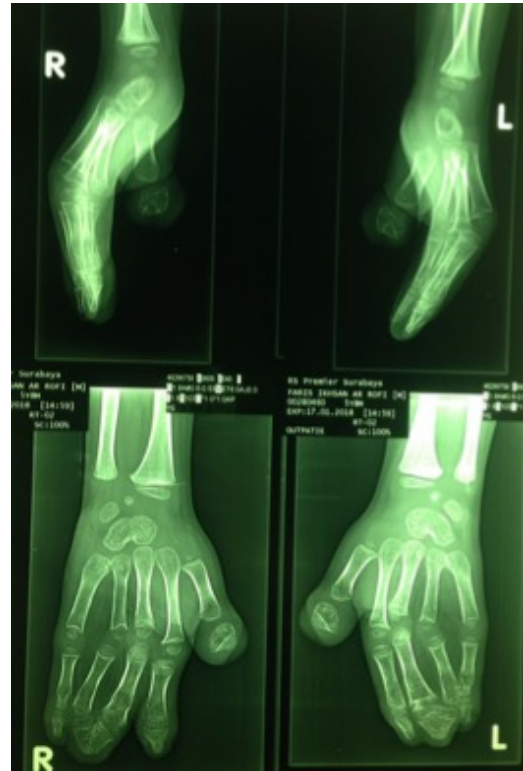
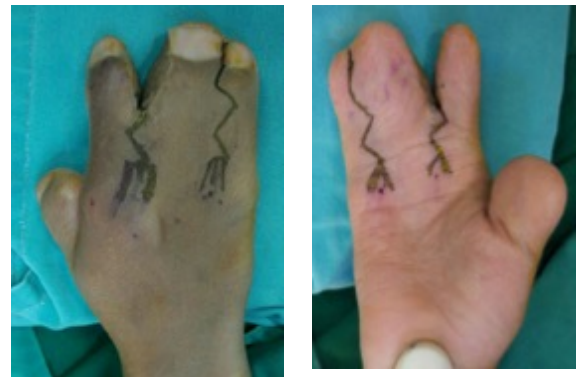
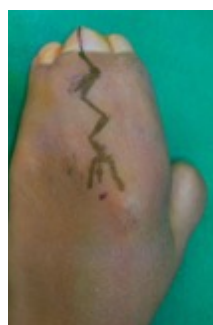Figure 25. Pre-surgery X-ray of right and left hand showing the bony fusion



A



B

Figure 26. Surgical design to release the web A. Right hand B. Left hand

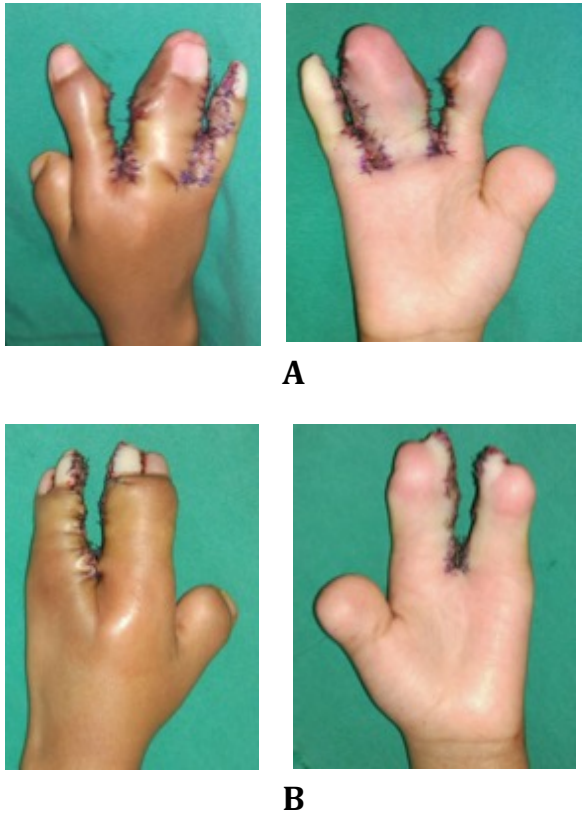


Figure 27. Early postoperative photos A. Right hand B. Left hand

Discussion

The syndactyly in Apert syndrome is one of the most challenging problems due to vast involvement of soft and hard tissue of the hand. There are many literatures which emphasizes many aspects in the surgical management of Apert hand syndrome. The primary goals on syndactyly operations are the capability to move the fingers freely in space, normal finger sensations and adequate covering, and also the ability to grasp objects with adequate power. There best period for syndactyly repair is 6 until 12 months of age. Reconstruction within this period will bring a maximum function and aesthetic outcome. Most of our patients were repaired after these period because of sosio-economic conditions.

There are a lot of additional principles that may be applied for the syndromic

syndactyly. Most guidelines suggest to perform the surgical management in several stages to assure the operation goals are achieved. One of the pre-surgery assessment in complex syndactyly is computed tomography (CT) angiograms, it can visualization of the arterial anatomy of the hand so the surgeon can choose single or multiple release of the web. In our institution, didn't perform the CT angiograms so we released the web in multiple operations.

Several techniques that are commonly used in the Apert hand surgery are: Dorsal rectangular flap, V shape palmar flaps, local rotation flaps, dorsal VY plasty, four flap z plasty, zig zag incisions, longitudinal incisions, free tissue transfers, Buck Gramcko's for nail fold reconstruction and combined with free flaps or a full-thickness skin graft are usually recommended to ensure adequate covering. External or internal fixation is sometimes used to guarantee the digit realignment. The techniques are plenty and are not perfect for one patient. Therefore the decision is tailored personally for each patient.

In our serial case, we combine dorsal rectangular flap for and palmar triangular flap are to make a new web space, Buck Gramcko pulp flap for the nail fold reconstruction, and full thickness skin graft were taken from the groin to cover the raw areas. Absorbable 5.0 simple interrupted sutures were used in each patient. Meticulous care was given for the wounds. Sterile soft gauze and soft cotton elastic band are used to compress the wounds to immobilize the skin grafts. Dressing is maintained for 3 until 5 days and wound evaluation is performed.

From the follow ups, we evaluate short term and long-term complication. Most common short-term complications are wound infection, maceration of the flap or grafts, graft failure. Short term complications might be caused by seromas, hematomas, and inadequate immobilization. Long term complication might be seen after quite some time, which includes: web creep, hypertrophic scars, joint instability, hyperpigmentation and hair growth (from

groin grafts), contractures, and nail deformities. All this patient in this serial case, has no serious complication at short or long term follow up.

Conclusion

The purpose of every principle technique is to obtain preferable outcome for normal digits, both in function and aesthetic. Choosing the surgical technique for releasing the web space in syndactyly depends on the patient condition and plastic surgeon's decision. In 5 patients that we had been followed up there was no meaningful complication attained from the postoperative result.

References

1. Thorne. C. Grabb and Smith's Plastic Surgery 7th edition. New York. 890-899.
2. Mathes S J. Plastic Surgery 2nd edition. San Fransisco California., Vol VIII.,139-174
3. Wolfe S W. 2011 Green's Operative Hand Surgery. 7th edition. Elsevier. New York. 1217-1230.
4. Fadda M T, Lerardo G, Ladniak B, et all. Treatment timing and multidisciplinary approach in Apert Syndrome. *Annali di Stomatologia* 2015: VI(2): 58-63.
5. Harvey I, MBBS, Brown S, et all. The Apert Hand - Angiographic Planning of a Single-Stage, 5-Digit Release for All Classes of Deformity. *J Hand Surg* 2012;37A:152-158.
6. Journeau P, Lajeunie E, Renier D, et all. Syndactyly in Apert syndrome Utility of a prognostic classification. *Ann Hand Surg.*1999.18:no 1,13-19.
7. Adrian E, Webbed finger. *Baylor University Medical Center Proceedings* 2005;18;26-37.
8. Braun T L, Trost J G, Pederson W C. Syndactyly Release. *Semin Plast Surg* 2016;30:162-170.
9. Kvernmo H D. Treatment of Congenital Syndactyly of the Fingers. *Tidsskr Nor Lægeforen nr. 15*, 2013: 113:1591-5.
10. Dao K D., Shin A Y, Billings A, et all. Surgical Treatment of Congenital Syndactyly of the Hand. *J Am Acad Orthop Surg* 2004; 12:39-48.
11. Jose R M, Timoney N, Vidyadharan R, et all. Syndactyly Correction: an Aesthetic Reconstruction. *The Journal of Hand Surgery* (European Volume, 2010) 35 E:6:446-450.