

# Foreign Body Extraction of a Push-pin nail with Granulation Tissue Complication on a Thirteen Years Old Male

Umi Fatma Octavia<sup>1</sup>, Ngakan Putu Parsama Putra<sup>1</sup>

<sup>1</sup>Department of Pulmonology and Respiratory Medicine, Saiful Anwar General Hospital, Brawijaya University

## Abstract

**Background:** Foreign body aspiration is common in children (80% in children under 5 years old) and elderly. The ratio in men is higher than in women. Flexible bronchoscopy is often used as a primary procedure in such cases because of its high sensitivity and specificity. However, in some cases, rigid bronchoscopy might be superior. This is a case report about a patient who came with complaints of bloody cough and chest pain after the ingestion of a push-pin nail. The patient underwent both bronchoscopic procedures.

**Case:** A 13-year-old male presented with complaints of sudden bloody coughing accompanied by chest pain in the middle area. Physical examinations were unremarkable, but images of spikes suggestive of a foreign object on the left hilus were found at the chest x-ray. A flexible fiberoptic bronchoscopy was performed immediately. A push-pin nail, located the left main bronchus with a sharp tip embedded in the mucosa and covered by granulation tissue, was identified. Evacuation attempts were unsuccessful. Rigid bronchoscopy was then performed and evacuation was carried out successfully. The patient was then discharged after forty-eight hours of close monitoring.

**Conclusion:** There are two types of bronchoscopy, flexible and rigid. Both have their respective advantages in the handling of patients with foreign bodies. Acquiring skills in operating both types of bronchoscopy are important for a bronchologist.

**Keywords:** Foreign body, Aspiration, Granulation tissue, Bronchoscopy

MRJ 2021; 3(1):101-107

## 1. Introduction

Foreign body aspiration is more common in children than in adults where 80% of cases occur in children aged 3 years or younger, with the peak occurrence occurring in the second year of life. At this age, children begin to stand up and putting everything into the mouth, yet still unable to chew properly. The airway protective mechanism is also relatively inefficient

despite the habit of crying, laughing, and playing while eating<sup>1</sup>.

Flexible bronchoscopy is usually used successfully in foreign body extraction, although rigid bronchoscopy preparations must be available and this procedure is used more often as a primary procedure in several health care centers<sup>2,3</sup>.

Flexible fiberoptic bronchoscopy is also used as a diagnostic tool to locate foreign

---

\* Corresponding author:

Umi Fatma Octavia (email)

Department of Pulmonology and Respiratory Medicine, RSUD Dr. Saiful Anwar Malang – Universitas Brawijaya, Jaks Agung Suprpto St. No. 2, Malang.65112, Indonesia

bodies in the airways. Flexible fiberoptic bronchoscopy has a sensitivity and specificity of almost 100% in diagnosing foreign bodies. In rare cases, this procedure can fail to pinpoint the location or evacuate a foreign body in the bronchus due to a thick granulomatous reaction around the foreign object or the presence of many bronchial secretions. Flexible fiberoptic bronchoscopy is recommended to be carried out if the clinical symptoms and or radiological examination results are inconclusive in detecting the presence of foreign bodies. When foreign bodies are found during the bronchoscopy procedure, extraction can be done directly. However, this is only possible with small objects. Other options that can be considered are rigid bronchoscopy. Rigid bronchoscopy is the first choice in handling foreign bodies and in some cases is more superior to the flexible one<sup>4</sup>. Here we present a case of foreign body extraction of a push-pin using rigid bronchoscopy.

## 2. Case

A 13 years old male, a student, came to a tertiary hospital with a chief complaint of aspiration of a push-pin nail  $\pm 1$ cm in size. On anamnesis, it was found that the patient coughed out approximately 5cc of blood right after the aspiration. The patient then continued to cough and experienced middle

chest pain particularly during coughing. Physical examination and laboratory workup including blood gas analysis were unremarkable. Upon Chest X-ray a spike-shaped metal density on left lung hilum projections as high as the 6th thoracic vertebra was found. A diagnosis of foreign body aspiration of push-pin was established (Figure 1A-B).

The patient underwent a flexible fiberoptic bronchoscopy. We observed a foreign body of a push-pin with the sharp tip facing upward embedded in the bronchial mucosa and the blunt end covered the left superior lobe orifice. Granulation tissue appeared to cover the said object. Foreign body extraction maneuver was performed but discontinued due to the risk of bronchial laceration and pneumothorax (Figure 2). Rigid bronchoscopy was then performed on the fourth day of admission. During the procedure, we discovered that the upper side of the nail was partially embedded in the mucosa and granulation tissue. Foreign body extraction was executed using rigid forceps with simultaneous removal of bronchoscopy. The object was successfully removed. Exploratory bronchoscopy reveals minimal bleeding and mucosal-deep laceration (Figure 3).

The patient is put under close observation for 48 hours. Chest x-ray evaluation showed no foreign object or

abnormalities (Figure 1C-D). The patient was then discharged.

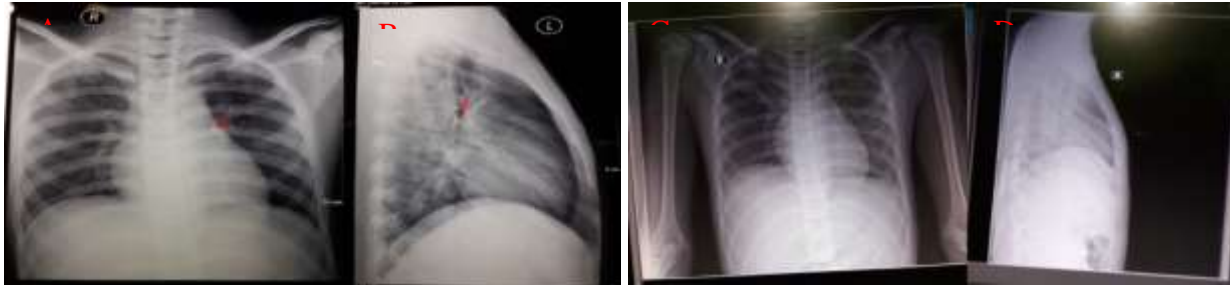

Figure 1 Comparison of Chest x-ray: A. Anteroposterior projection (AP) B. Left lateral projection (taken on 13<sup>th</sup> Februari 2017), Initial chest x-ray showed a spike shaped metal density on the left hilum at the level of 6<sup>th</sup> thoracic vertebrae. C. Anteroposterior projection (AP) D. Left lateral projection (taken on 17th Februari 2017) Chest x-ray after rigid bronchoscopy extraction, pulmos are normal and no foreign body found.

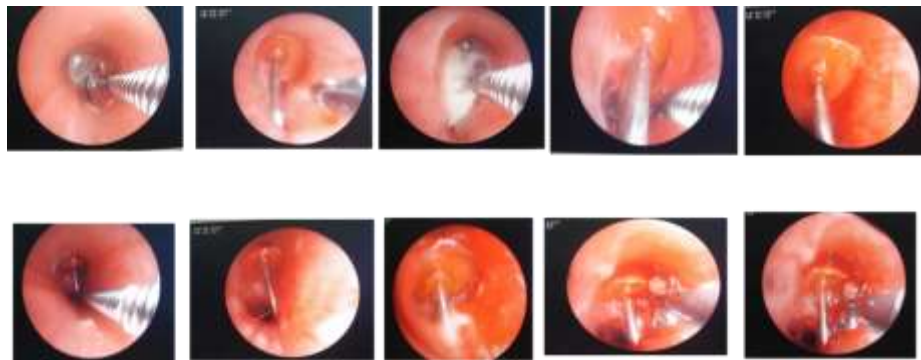


Figure 2. Flexible bronchoscopy (14th February 2017) reveals a pushpin in main left bronchus with the sharp part embedded to the mucosa and covered by granulation tissue.

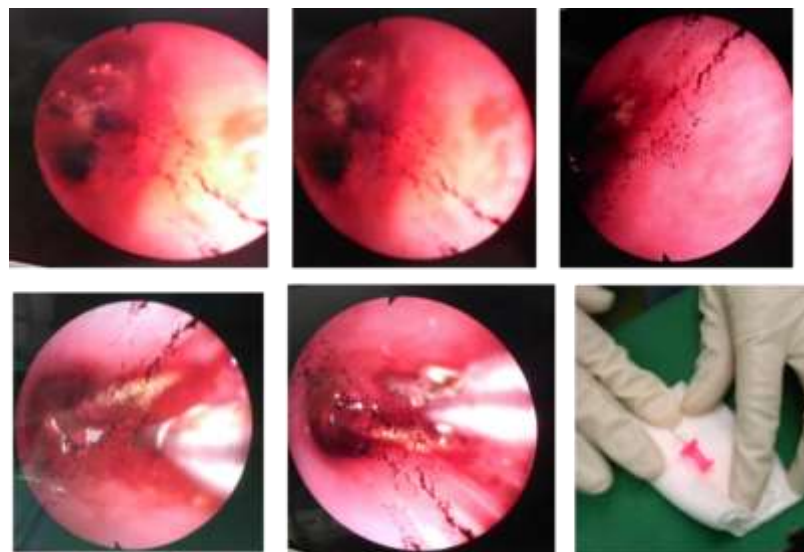


Figure 3. Rigid bronchoscopy exploration and extraction performed on 17th February 2017. Pushpin is successfully removed from main left bronchus.

### 3. Discussion

Epidemiologically, foreign body aspiration is more common in children (80% age <3 years) and is more dominant in men (ratio of women compared to 17-2, 4:1)<sup>5</sup>. The most common types of foreign bodies in children include nuts or seeds. Meanwhile, the object may vary for adults<sup>6</sup>. In our case, the patient bites the push-pin nail for comedic intention. Negligence and carelessness are clear predisposing factors as to why such an unfortunate accident happens.

The patient experienced bloody coughing shortly after the ingestion of the pushpin nail. He also felt throat pain a few moments later. A patient who aspirates a foreign body will experience a sudden onset of severe coughing, choking, gagging, stuttering, and obstructive breathing. In the next stage, the complaints will gradually subside (asymptomatic) since the foreign body entered the lower respiratory tract. At the final stage, complications occur due to obstruction, erosion, and or infection. This might cause cough, hemoptysis, pneumonia, and lung abscess<sup>7</sup>.

In the case of food or drink aspiration, the esophagus is anatomically located behind the throat (airway). Both of these channels are related to the nostrils and mouth. The valve (epiglottis) acts as a door leaf

alternately closing and opening the throat. During the breathing process, the valve closes the esophagus so that air goes into the throat. On the contrary, when swallowing foods, the valve closes the throat so that food can pass through the esophagus. Choking can occur when food that is supposed to go down the esophagus goes down to the throat instead<sup>7</sup>.

In our case, all physical examinations were unremarkable. According to the previous studies, the physical examination from foreign body aspiration in children is mostly within the normal limit (89% of the cases). Despite normal physical examination, clinical suspicion must remain high because anamnesis supports the possibility of foreign body aspiration<sup>1,8</sup>.

In laboratory tests, there was no increase in leukocytes. Blood chemistry and physiological hemostasis were within normal limits. Laboratory tests on foreign body aspiration cases were carried out to determine acid-base balance disorders and signs of infection<sup>7</sup>.

A foreign body, metal density on the projections of the left bronchus as high as the 6th vertebrae, was found on Chest X-ray. Foreign bodies in the bronchus most often occur in the right bronchus. This is because in comparison to the left counterpart, the

right bronchus has a bigger anatomical shape, greater airflow, and a smaller angle to the trachea<sup>7</sup>. However, in this case, a foreign body was found in the left bronchi.

Radiological examination is an aid in diagnosing foreign bodies in the aerodigestive tract. Although radiological imaging might appear normal in the first 24 hours, this doesn't exclude the possibility of a foreign body. Radiopaque foreign bodies are easy to diagnose, whereas radiolucent foreign bodies such as organic matter are more complicated. Standard posterior-anterior (PA) cervical and thoracic examinations are preferred for cases with suspected foreign body aspiration. Research by Kosucu et al. found that multiple-detector CT virtual bronchoscopy has 100% sensitivity and specificity in detecting foreign bodies<sup>4,8</sup>.

The patient underwent a flexible fiberoptic bronchoscopy examination. On this procedure, it appeared that the foreign body (push-pin nail) located in the left main bronchus, wrapped in granulation tissue, the sharp end of the nail embedded in the bronchial mucosa and the blunt part covered the bronchial orifice. The bronchoscopy examination confirms the presence of foreign objects in the airway's pushpin nails as per the projections on AP and lateral chest X-ray examination. Fiberoptic bronchoscopy is

used as a diagnostic tool to locate the foreign body in the airway. Should the said objects were found during the procedure, extraction can be carried out immediately. Flexible fiberoptic bronchoscopy plays an important role in the diagnosis of foreign bodies in the airways because the sensitivity and specificity are almost as high as 100%<sup>4</sup>. This procedure is the main choice for an adult case of foreign body aspiration. In our case, following the failure of extraction under the flexible fiberoptic bronchoscopy, the foreign body was extracted using forceps in rigid bronchoscopy. The flexible fiberoptic bronchoscopy was unsuccessful due to the complications of granulation tissue covering the foreign body. The risk of bronchial laceration was apparent thus complicating the extraction effort. Complications in the form of granulation tissue can occur within the first 48 hours after the entry of the foreign matter. Foreign bodies that enter and injure the inside of the airways cause the wound healing response forming granulation tissue. This tissue is rich in vascularization and components of white blood cells. The tissue is pink-colored and bleeds easily.

The patient then underwent a rigid bronchoscopy procedure on day 4 of the admission. Rigid bronchoscopy managed to evacuate the foreign object (a ±1cm push-

pin). Here, rigid bronchoscopy has an advantage over flexible optic fiber bronchoscopy due to its large caliber. This allowed freer airway manipulation and ensured a smooth flow of respiratory air. Hence the foreign objects can be freed and evacuated with minimal risk. The decision to choose which procedure to be performed depends on the skill and experiences of the bronchologist. Therefore, becoming proficient in both bronchoscopy procedures is advisable for a bronchologist.

#### 4. Conclusion

Foreign body aspiration is more common in children than in adults. Normal physical examination findings and supporting exams do not exclude the possibility of foreign body aspiration. Suspicion must remain high if the history permitted. Flexible fiberoptic bronchoscopy is the first choice in the diagnosis and treatment of foreign bodies. However, an evacuation attempt using flexible fiberoptic bronchoscopy was unsuccessful due to granulomatous tissue complications. The push-pin was then successfully removed using rigid fiberoptic bronchoscopy with minimal bleeding and mucosal-deep laceration.

#### References

1. Dickenson O, Usalan C, Filiz A. 2002. Foreign Body Aspiration: Clinical Utility of Flexible Bronchoscopy. *Postgrad Med Journal* Vol 78; pp. 399-403.
2. Estella A. 2012. Bronchoscopy in Mechanical Ventilated Patients in Global Perspective of Bronchoscopy. Chapter 5.
3. Gay SB, Shaffer HA, Vu QDM, Marker CO, Kuzminski CD, Christensen JD, Bassignani MJ, Lange EE, Brant WE, Lamber DL, Padgett AV, Blount KJ, Momenian SH, Wasti MF, Fakhran S, Ho CP, Tatineny KC, Kori GA. 2013. Introduction to Gastrointestinal Radiology. University of Virginia, Health Sciences Center, Departement of Radiology. [www.med-ed.virginia.edu/diaksestanggal](http://www.med-ed.virginia.edu/diaksestanggal) 8 Oktober 2015
4. Hitter A, Hullob E, Durand C, Righini CA. 2011. Diagnostic Value of Various Investigations in Children with Suspected Foreign Body Aspiration Review. *European Annuals of Otorhinolaryngology, Head and Neck diseases* Vol.128. pp. 248-52.
5. Kaushal P, Brown DJ, Lina L, Bretzke S, Shah RK. 2011. Aspirated Foreign Bodies in Pediatric Patients, 1968-2010: A Comparison Between the US and Other Countries. *International Journal of Pediatric Otorhinolaryngology* Vol 75; pp. 1322-1326.
6. Marquette CH, Martinot A. 2000. Foreign Body Removal in Adult and Children. *Interventional Bronchoscopy*. Karger, Basel, pp. 96-106.
7. Junizaf M. 2007. Benda Asing di Saluran Napas, dalam Soepardi E, Iskandar N, Bashiruddin J, Restuti R. *Buku Ajar Ilmu Kesehatan THT-KLE* edisi 6. Jakarta. Balai Penerbit FKUI. pp. 259-65.
8. Schoem SR, Rosbe KW, Beareilly S. 2015. *Cumming Otolaryngology: Aerodigestive Foreign Body and Caustic Ingestion*. 6th Ed. ElviesierSauders: Philadelphia. pp. 3185-6.