

Article

The Specific Growth Rate (SGR) Related to the Histology of Gonad and Liver of African Catfish (*Clarias gariepinus*) Supplemented with Curcumin and Thyroxine Hormone

Article Info

Article history :

Received September 29, 2020
Revised March 15, 2021
Accepted March 18, 2021
Published June 27, 2021

Keywords :

Clarias gariepinus,
curcumin, Histology,
SGR, Thyroxine

Livana Dethris Rawung^{1*}, Ade Sunarma², Debby J.J Rayer¹

¹Department of Biology, Faculty of Mathematics and Natural Science (FMIPA), Universitas Negeri Manado, Indonesia

²National Freshwater Aquaculture Center, Ministry of Marine Affairs and Fisheries, Republic of Indonesia, Jalan Selabintana 37, 43114 Sukabumi, Indonesia

Abstract. This study used catfish *Clarias gariepinus* as an experimental animal, which given supplementation of curcumin and thyroxine hormone. The results showed that during the reproductive period there was an increase in body weight of female catfish in line with the development of the gonads. Through the histology of the gonads, it appeared that oocyte development occurs over time. The results of liver histology showed a high activity of hepatocyte cells as indicated by the formation of vacuoles, as the storage site for vitellogenin, in their cytoplasm. Supplementation of curcumin and thyroxine was able to increase the specific growth rate of catfish, and the catfish group that given the combination treatment of curcumin supplementation (5 g.kg⁻¹ of feed) with thyroxine hormone (0.1 mg.kg⁻¹ of feed) showed the more optimal results.

This is an open acces article under the [CC-BY](https://creativecommons.org/licenses/by/4.0/) license.



This is an open access article distributed under the Creative Commons 4.0 Attribution License, which permits unrestricted use, distribution, and reproduction in any medium, provided the original work is properly cited. ©2021 by author.

Corresponding Author :

Livana Dethris Rawung
Department of Biology, Faculty of Mathematics and Natural Science (FMIPA),
Universitas Negeri Manado, Indonesia
Email : livana83@yahoo.com

1. Introduction

The female broodstock body weight will increase during the reproductive period due to the development of a new individual candidate in the uterus/gonads. In oviparous animals, for example, fish, the development of gonad influenced by the increase in the diameter of the oocyte.

The increase in oocyte diameter occurs due to the accumulation of the precursor materials of the egg yolk into the oocytes. Vitellogenin is the main precursor of egg yolk synthesized by hepatocyte hepatic cells. During this period the activity of hepatocyte cells is high due to the ongoing synthesis of vitellogenin [1,2].

As long as the reproductive period, there are physiological changes that affect the appearance of the tissues of the reproductive organs (especially gonad and liver in oviparous animals) [3]. The microanatomy of animal tissue can be studied by histology. The technique of making histological tissue preparations is often referred as histotechnics. The paraffin method is a histotechnical slice preparation method that is routinely used in the preparation of histological and histopathological preparations, by the coloring we can know the the changes that happen in that tissues [4].

Curcumin is a compound found in rhizome plants such as turmeric. Curcumin has various bioactivities such as antioxidants, hepatoprotectors, phytoestrogens and so on [5-7]. Curcumin application to fish has shown a positive effect on increased production [8-10]. The bioactivity of curcumin in the form of a hepatoprotector provides protection against the liver of oviparous animals thereby optimizing its physiological function, and optimizing the activity of vitellogenin synthesis by hepatocyte during the reproductive period [2,11-12].

Thyroxine is the main hormone that has function in increasing the rate of formation of adenosine triphosphate (ATP) as cellular energy [13]. The availability of cellular energy in the form of ATP can help optimize cellular activity, especially during the reproductive period. Several studies have shown that administration of the hormone thyroxine can optimize fish growth [14-16]. Likewise, research conducted on the application of the hormone thyroxine during the reproductive period in catfish can optimize the number of spawned eggs [10].

The purpose of this study was to determine the effect of curcumin and thyroxine supplementation on the specific growth rate of catfish associated with gonad and liver histology during the reproductive period.

2. Experimental Section

2.1 Experimental Design

The experimental design used was a completely randomized design with 4 treatments. Each treatment consisted of 4 replications and each replication consisted of 8 catfish. The four treatment groups are:

- A = 0.0 g curcumin kg^{-1} feed + 0.0 mg thyroxine kg^{-1} feed;
- B = 5 g curcumin kg^{-1} feed + 0.0 mg thyroxine kg^{-1} feed;
- C = 0.0 g curcumin kg^{-1} feed + 0.1 mg thyroxine kg^{-1} feed;
- D = 5 g curcumin kg^{-1} feed + 0.1 mg thyroxine kg^{-1} feed.

2.2 Experimental Procedure

The female catfishes were used as the experimental animal in this study. Those catfishes were reared in 16 nets (2 x 1 x 1m³), each net contains eight fishes. Before treatment, the catfishes were acclimated for one week. After the period of acclimation, the fishes were given supplementation of curcumin and thyroxine hormone for nine weeks.

Every three weeks, samples were collected by measuring the weight of fish biomass to find out the rate of the bodyweight increases. For analysis of histology, every replication from all treatment was taken one fish to dissect to take the liver and gonad organs. The gonads and livers were then fixed using 10% formalin. After the fixation is carried out, it is followed by a process of dehydration, clearing, embedding, sectioning, and ending with staining. After staining the object was then observed under a microscope.

The Specific Growth Rate (SGR) Related to the Histology of Gonad and Liver of African Catfish (*Clarias gariepinus*) Supplemented with Curcumin and Thyroxine Hormone

2.3 Parameters

2.3.1 Specific Growth Rate (SGR)

The SGR measured by following formula [17]:

$$\text{SGR (\%/day)} = \frac{\text{Ln}Wt - \text{Ln}Wo}{t} \times 100\%$$

Note :

- SGR : Specific Growth Rate (%.day⁻¹)
- Wo : Average fish weight at the beginning of rearing (g)
- Wt : Average fish weight at the end of rearing (g)
- t : Rearing time (day)

2.3.2 Histology

The histological preparations were made using the paraffin method with hematoxylin- eosin staining [4]. The stained preparation then observed under a microscope.

2.4 Statistical analyses

The data obtained were analyzed by analysis of variance (ANOVA) using MINITAB version 16. Differences in the mean value of the treatments were tested using the Tukey test. Different treatments were evaluated at a significant level of $p < 0.05$. Histological data are displayed in the form of images and discussed descriptively.

3. Results

3.1 Specific Growth Rate (SGR) of African catfish given supplementation of curcumin and thyroxine hormone for 9 weeks.

Curcumin and thyroxine supplementation showed a difference ($p < 0.05$) between treatments at the specific growth rate (SGR) (Figure 1). The SGR statistical analysis showed that the highest SGR was found in catfish supplemented with curcumin and thyroxine (Group D; $1.01 \pm 0.9\%$), followed by catfish supplemented with thyroxine without curcumin (Group C; $0.92 \pm 0.05\%$), catfish that were supplemented with curcumin without thyroxine (Group B; $0.82 \pm 0.08\%$), and catfish that were not supplemented with curcumin and thyroxine (Group A / control; $0.76 \pm 0.03\%$). Tukey's test showed that catfish supplemented with curcumin and thyroxine (Group D) did not differ ($p > 0.05$) compared to catfish supplemented with thyroxine without curcumin (Group C), but there were significant differences compared to catfish supplemented with curcumin without thyroxine (Group B) and catfish that were not supplemented with curcumin and thyroxine (Group A).

3.2 Histology of liver and gonads organs after 9 weeks of treatment

Histological observations of catfish liver tissue showed the accumulation of egg yolk precursors in the cytoplasm as shown by the formation of vacuoles in the cytoplasm of hepatocytes. The formation of vacuoles was detected at the beginning of the observation as shown in Figure 2. The highest vacuole formation was the same in all treatments, which was seen at week 3. This vacuole formation was still observed until the 9th week of sampling. However, it appears that the formation of vacuoles in week 9 was less than the previous observation weeks.

The histological observation of the gonadal tissue showed an increase in the diameter of the oocyte from the initial observation to the 9th week of sampling, which was in line with the enlargement of the gonads. At the beginning of the observation, it appears that there is the same

oocyte variation in each treatment. The histological results of the gonad tissue at the beginning of this observation indicate that there are still oogonia stages, some of the primary oocytes have even reached the secondary oocytes, which are still dominated by oogonia and primary oocytes. In the third week of observation, it was clear that the vitellogenesis process was taking place, as indicated by the sight of several oocytes with yolk globules. These egg yolk granules are compensation for the activity of vitellogenin deposits by each developing oocyte. In line with the increase in maintenance time, it appears that there are more oocytes in the yolk globules stage as well as more in diameter. In the sixth and ninth weeks, the histology of the gonadal tissue showed that the oocytes were almost uniform in size (Figure 3).

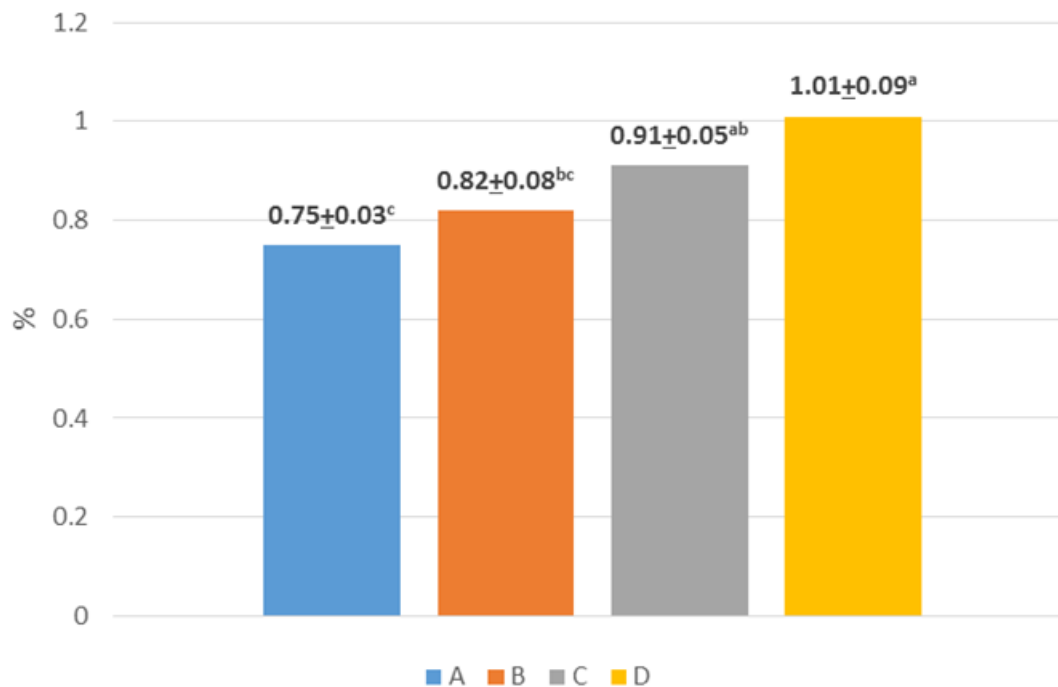


Figure 1. Specific Growth Rate (%) of African catfish that given supplementation of curcumin and thyroxine hormone

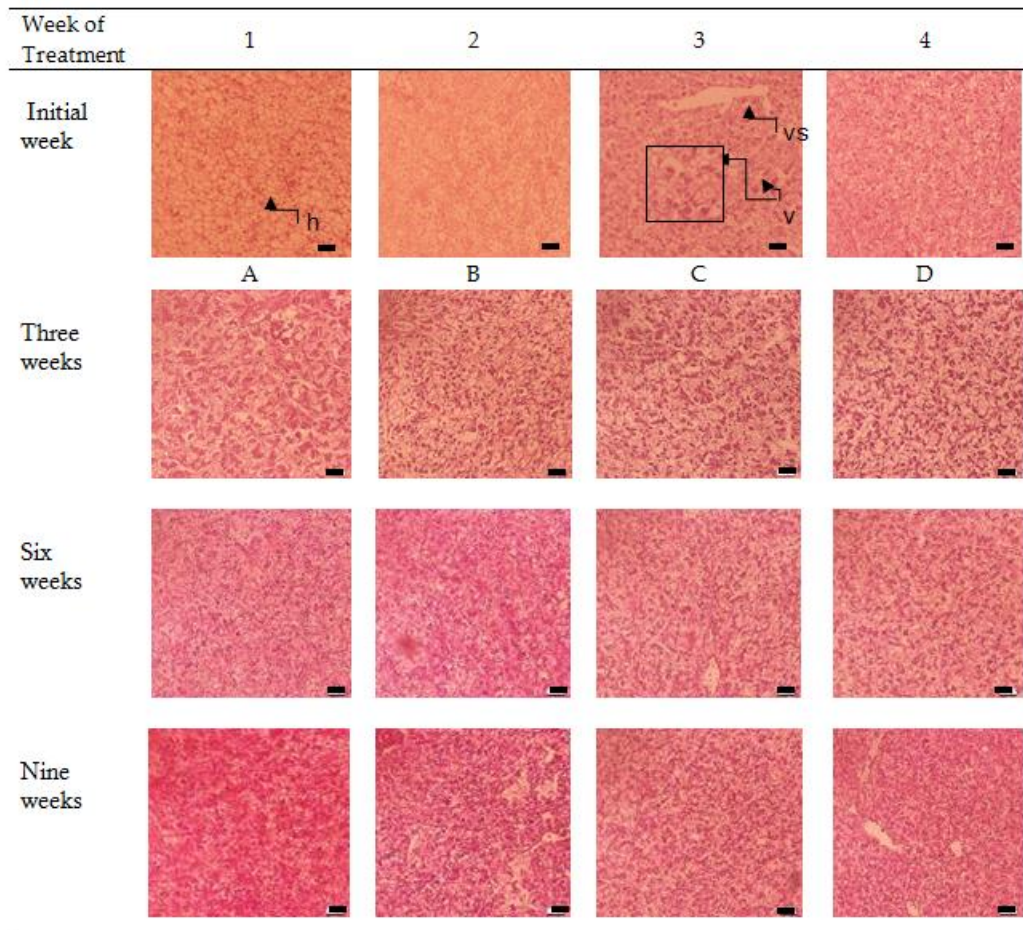


Figure 2. The histology of African catfish liver that supplemented by curcumin and thyroxine hormone ((Vena central (vs), vacuola (v), hepatocyte (h). Staining with hematoxylin- eosin, scale line represented 20 μ m. Enlargment 40 x 10 times)

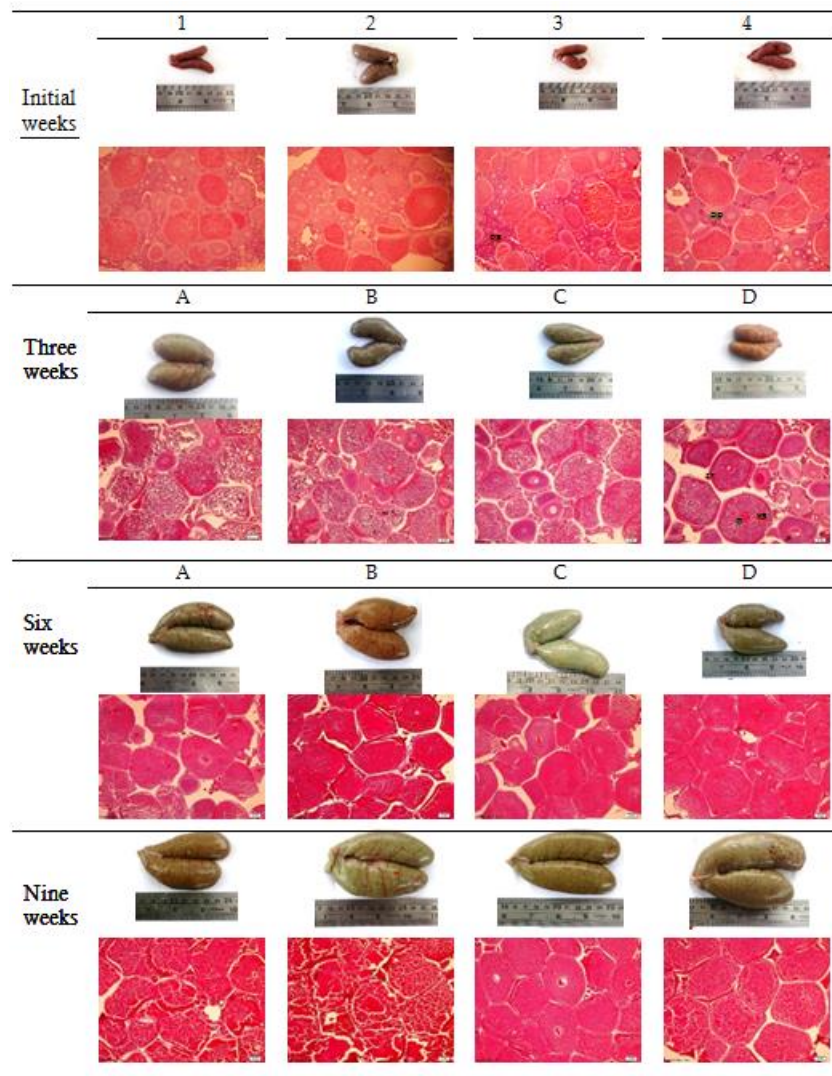


Figure 3. The development and histology of gonads that supplemented with curcumin and thyroxine hormone ((**Og** (oogonia); **zr** (zona radiate); **op** (oosit primer); **yg** (yolk globules); **n** (nucleus)). Staining with hematoxylin- eosin, Scale line represented 20 μ m. Enlargement 40 x 10 times)

4. Discussion

The increase in the specific growth rate of catfish in this study was strongly influenced by gonad weight gain. The results showed that the oocyte was a development over time in all treatment groups. However, it appears that at the end of the observation the groups given supplementation of both curcumin and thyroxine alone or a combination of both, have the larger size of gonads than the control. Likewise, the histology of the gonadal tissue shows that there is an increase in the diameter of oocytes from time to time which influenced by the accumulation of vitellogenin in these oocytes. Meanwhile, curcumin supplementation in catfishes was able to increase the value of the gonadal

somatic index (GSI) and oocyte diameter [1,10]. However, studies conducted on goldfish showed that curcumin supplementation could decrease GSI values but increase oocyte diameter [9].

During the reproductive period, there are fluctuations in the concentration of nutrients in the blood circulation in catfish [18]. The fluctuations of the nutrient thought as the influence of the activity of the hepatocyte cells to absorb the nutrient for synthesizing vitellogenin. Through the histology of the liver tissue, it appears that many vacuoles are formed in the liver cells. These vacuoles contain nutrients that are components of vitellogenin synthesized by liver cells [1,3]. The results of catfish liver histology showed that from the beginning of the observation to the 9th week there was a vacuole formation in the liver cells. The formation of the vacuole is in line with the development of the gonads. Gonadal development occurs due to an increase in oocyte diameter. The deposits of vitellogenin in oocytes cause an increase in the diameter of the oocytes [19].

Research conducted by Dewi *et al.* [1] in catfish supplemented with turmeric flour showed an increase in the accumulation of egg yolk precursors in the cytoplasm during the reproductive period. The histomorphology of the livers of the ducks treated with curcumin showed larger hepatocyte vacuoles containing fat granules [3]. The increase in the size of the vacuole indicates an increase in the storage capacity of liver cells to store organic material, such as vitellogenin as a precursor for egg yolk before being secreted into the bloodstream for further deposition into developing oocytes. The appearance of a vacuole in the liver is often a parameter of histological liver damage. However, in this condition, the vacuolization that occurs is part of the ongoing reproductive activity in catfish.

Observations during the rearing period showed that the experimental fish, apart from experiencing an increase in body weight due to reproductive activity, were also still undergoing a process of growth and development as indicated by an increase in body length. The results of this study also indicated that thyroxine supplementation significantly increased the bodyweight of experimental fish compared to those not given thyroxine supplementation. This can illustrate that in addition to the increase in body weight due to gonad development, there is also the formation of body protein mass in fish. Thyroxine supplementation appears to increase the metabolic rate by increasing the amount of cellular energy produced [13]. The sufficient source of energy and nutrients needed by cells allows metabolic activity in cells to occur optimally. This can be seen through the optimization of growth in fish supplemented with the hormone thyroxine [15,16].

5. Conclusion

Supplementation of curcumin and thyroxine hormone was able to increase the specific growth rate of catfish, and the catfish group that was given a combination treatment of curcumin supplementation (5 g.kg⁻¹ of feed) with thyroxine hormone (0.1 mg.kg⁻¹ of feed) showed more optimal results.

6. Acknowledgement

The authors want to say thank you to the National Freshwater Aquaculture Center Sukabumi for permission allowing us to use all of the facilities that we need.

References

- [1] Dewi, C.D; Manalu, W; Ekastuti, D.R; Sudrajat, A.O. (2018). The role of the turmeric powder supplementation in improving liver performance to support the production of siam catfish (*Pangasianodon hypophthalmus*). *Omni-Akuatika*,14(1), 44-53.
- [2] Rawung, L.D; Ekastuti, D.R; Sunarma, A; Junior, M.Z; Rahminiwati, M; Manalu, W. (2021). Effectivity of Curcumin and Thyroxine Supplementations for Improving Liver Functions to Support Reproduction of African Catfish (*Clarias gariepinus*). *Jordan J. Biol. Sci.* Volume 14, Nomor 1.

- [3] Kasiyati. (2017). Sulementasi Kurkumin dan Peran Cahaya Monokromatik untuk Mengoptimalkan Biosintesis Telur Itik Lokal. Disertasi, Institut Pertanian Bogor, Bogor.
- [4] Bancroft JD, Gamble M.(2008). *Theory and practice of histological techniques*. 6thed. Churchill Livingstone, Elsevier, China.
- [5] Anand, P; Sundaram, C; Jhurani, S; Kunnumakkara, A.B; Aggarwal, B.B. (2008). Curcumin and cancer: An “old-age” disease with and “age-old” solution. *Cancer letters* : 267, 133-164.
- [6] Bachmeier, B.E; Mirisola, V; Romeo, F; Generoso, L; Esposito, A; Dell’Eva, R; Blengio, F; Killian, P.H; Albin, A; Pfeffer, U. (2010). Reference profile correlation reveals estrogen-like transcriptional activity of curcumin. *Cell Physiol Biochem*, 26, 471-482.
- [7] Zhao, S.G; Li, Q; Liu, Z.X; Wang, J.J; Wang, X.X; Qin, M; Wen, Q.S. (2011). Curcumin attenuates insulin resistance in hepatocytes by inducing Nrf2 nuclear translocation. *Hepatogastroenterology*, 58 (112), 2106-2111.
- [8] Dewi, C.D; Ekastuti, D.R; Sudrajat, A.O; Manalu, W. (2018). Improved vitellogenesis, gonad development and egg diameter in catfish (*Panasianodon hypophthalmus*) supplemented with turmeric (*Curcuma longa*) powder. *Aquac. Res*, 49(2), 651-658.
- [9] Rawung L.D; Saruan J. (2020). Effectiveness of curcumin supplementation in feed on liver productivity and reproductive performance of female carp *Cyprinus carpio* L. *Indonesian Biodiversity Journal*, 1(1), 22-33
- [10] Rawung, L.D; Ekastuti, D.R; Junior, M.Z; Rahminiwati, M; Sunarma, A; Manalu, W. (2020). Reproductive performances and egg qualities in African catfish (*Clarias gariepinus*) broodstocks supplemented with curcumin and thyroxine hormone. *Omni-Akuatika*, 16(1), 32-47.
- [11] Kasiyati; Sumiati; Ekastuti, D.R; Manalu, W. (2016). Roles of curcumin and monochromatic light in optimizing liver function to support egg yolk biosynthesis in magelang duck. *Int Poult Sci*, 15, 414-424.
- [12] Saraswati, T.R; Manalu, W; Ekastuti, D.R; Kusumorini, N. (2013). Increased egg production of Japanese quail (*Cortunix japonica*) by improving liver function through turmeric powder supplementation. *Int J Poult Sci*, 12(10), 601-614.
- [13] Guyton, A.C; Hall, J.E. (2006). *Textbook of medical physiology, eleventh edition*. Elsevier Saunders. Pennsylvania.
- [14] Ayson, F.G; Lam, T.J. (1993). Thyroxine injection of female rabbitfish (*Siganus guttatus*) broodstock: changes in thyroid hormone levels in plasma, eggs, and yolk-sac larvae, and its effect on larval growth and survival. *Aquaculture*, 109(1), 83-93.
- [15] Agusnimar; Rosyadi. (2015). Pertumbuhan dan kelangsungan hidup ikan selais *Kryptopterus lais* yang diberi hormone tiroksin. *JAI*, 14(1), 38-41
- [16] Zairin, M.Jr; Pahlawan, R.G; Raswin, M. (2005). Pengaruh pemberian hormone tiroksin secara oral terhadap pertumbuhan dan kelangsungan hidup ikan Platali Koral *Xiphophorus maculates*. *JAI*, 4, 31-35
- [17] Zenneveld, N; Huisman, E.A; Boon, J.H. (1991). Prinsip-prinsip budidaya ikan. PT. Gramedia Pustaka Umum, Jakarta.
- [18] Rawung, L.D; Ekastuti, D.R; Rahminiwati, M; Sunarma, A; Junior, M.Z; Manalu, W. (2019). The blood chemistry profile of African catfish (*Clarias gariepinus*) Broodstock that supplemented with curcumin and thyroxine hormone during vitellogenesis. *Int. J. Sci: Basic Appl Res*, 4(4), 213-223.
- [19] Revathi, P; Iyapparaj, P; Munuswamy, N; Krishnan, M. (2012). Vitellogenesis during the ovarian development in freshwater female prawn *Macrobrachium rosenbergii* (De Man). *Int. J. Aqu. Sci*. 3(2), 13-27.