

Case Report:**LOW VISION MANAGEMENT IN A 5-YEARS-OLD DUE TO RETINOPATHY OF PREMATURETY FOR LIFE QUALITY IMPROVEMENT****Aritonang Christina**

Refraction, Contact Lens and Low Vision Division, Department of Ophthalmology, Faculty of Medicine, Airlangga University, Dr. Soetomo General Hospital, Surabaya, Indonesia

ABSTRACT

Management of low vision in pediatric patients with greater result can affect their quality of life than in adult low vision patients. Retinopathy of prematurity is the main cause of blindness in children. A case study highlights the tertiary prevention (low vision examination and management) in a 5 year old boy with ROP related blindness to optimize his remaining visual capacity by using optical and non-optical aids that support daily activity and educational learning. A 5-year-old boy with ROP related blindness visited to the low vision clinic after receiving the several treatments for ROP before. His visual acuities were light perception in the right eye and hand movement in the left eye using his current spectacle correction. He had anti VEGF bevacizumab intravitreal injection, vitrectomy and complicated cataract extraction history on the left eye. He was difficult to learn and read numbers and alphabets caused by visual impairment. Upon evaluation by assessment low vision method, his distance visual acuity in the left eye was improved significantly up to 3/40 on LEA Acuity chart with +14.00D. His near vision became 10 M at 30 cm of reading distance (without near correction) and 4 M at 13 cm improved with +3.00 D by spectacle. The non-optical aid devices as reading task were also suggested to improve continuous reading text without difficulty. ROP blindness can be preventable if appropriate, adequate and accessible screening programmes are available. Unfortunately, even with the current screening guidelines and recommended treatment of ROP, many babies suffer from blindness by this disease each year. Low vision assessment and management in pediatric patient with visual impairment according to children need can optimize the recent visual capability of low vision patient and give selfcare daily activity and educational learning.

Keywords: *Low vision assessment and management; retinopathy of prematurity; quality of life*

ABSTRAK

Low vision dapat terjadi pada pasien pediatri dan penanganannya lebih menjanjikan dibandingkan pada dewasa. Retinopathy of prematurity masih menjadi penyebab utama kebutaan pada anak-anak. Studi kasus ini berfokus pada pencegahan tersier (pemeriksaan dan penanganan low vision) pada anak dengan kebutaan terkait ROP agar dapat mengoptimalkan visual yang tersisa dengan memberikan pemilihan alat bantu optik dan non optik yang mendukung aktivitas sehari-hari dalam mobilisasi dan mendukung untuk kemampuan belajar anak. Anak laki-laki usia 5 tahun dengan kebutaan terkait ROP datang ke klinik low vision setelah mendapatkan beberapa terapi terkait ROP. Visus saat pertama kali datang adalah persepsi cahaya di mata kanan dan 1/300 di mata kiri dengan penggunaan kacamata. Pasien telah mendapatkan injeksi intravitreal anti VEGF bevacizumab sebelumnya, dan telah dilakukan vitrektomi, serta riwayat ekstraksi katarak komplikata pada mata kiri. Pada saat datang oleh keluarga dikeluhkan kesulitan membaca angka dan huruf akibat keterbatasan penglihatannya. Setelah dilakukan pemeriksaan khusus low vision didapatkan visus jarak jauh mata kiri membaik secara signifikan menjadi 3/40 dengan +14.00 D. Pemeriksaan visus jarak dekat 10M pada 30cm tanpa kacamata dan 4M pada jarak 13cm dengan bantuan kacamata +3.00D. Alat bantu non optikal juga disarankan dengan penyangga buku bacaan untuk mengurangi hambatan dalam membaca tulisan (teks) dengan cepat. Kebutuhan akibat ROP dapat dicegah apabila program penapisan dilakukan dengan tepat, adekuat, dan mudah diakses. Penatalaksanaan low vision dengan melakukan assessment dan manajemen (penatalaksanaan) yang sesuai dengan kebutuhan anak diharapkan dapat memperbaiki kualitas hidup dengan mengoptimalkan sisa penglihatan yang masih ada pada anak dengan low vision dan memberikan kemandirian di kemudian hari.

Kata kunci: *Penatalaksanaan low vision; retinopati prematuritas; kualitas hidup*

Correspondence: Christina Aritonang, Faculty of Medicine, Universitas Airlangga, Dr. Soetomo General Hospital, Surabaya, Indonesia. E-mail: christinamd.19@gmail.com

INTRODUCTION

Low vision is a permanent visual impairment, broadly defined as a best-corrected visual acuity (BCVA) worse than 20/40 in the better eye, substantial visual field loss, or substantial loss of contrast sensitivity, that is not correctable by refraction, medical treatment, or surgery (Fontenot et al 2018). In the 2016 version of the International Classification of Disease (ICD)-10, visual impairment is classified in 5 categories based on presenting visual acuity. While older definitions were based on best visual acuity of the better eye, the current definition is based on presenting visual acuity (with glasses is any, without glasses if not) in order to emphasize the burden of uncorrected refractive errors. According to this, presenting visual acuity in the better eye equal to or better than 6/18 is defined as mild or no visual impairment; equal to or better than 6/60 and worse than 6/18 as moderate visual impairment (category 1); equal to or better than 3/60 and worse than 6/60 as severe visual impairment (category 2); and worse than 3/60 as blindness. Blindness is also separated into 3 categories: visual acuity worse than 3/60 (category 3), worse than 1/60 (or counting finger at 1 meter) (category 4), and no light perception (category 5). Base on this classification, those with moderate and severe visual impairment (visual acuity worse than 6/18 and equal to or better than 3/60) and those with a visual field less than or equal to 20 are defined as having low vision and require rehabilitation (Fontenot et al 2018, Şahlı & İdil 2019).

According to World Health Organization (WHO) data from 2010, there were an estimated 285 million people living with visual impairment worldwide. Of these, 39 million were reported as blind and 246 million as having low vision. The prevalence and causes of blindness and low vision in different societies vary based on their level of development. In 2010, there were an estimated 2.9 million people in the United States aged 40 years or older with low vision. In the United States, low vision is most commonly caused by age-related macular degeneration (AMD), glaucoma, and diabetic retinopathy (DR). Low vision can also affect pediatric patients due to a variety of genetic or acquired diseases (Şahlı & İdil 2019, Shah et al 2018).

One of the acquired diseases that causes pediatric low vision is retinopathy of prematurity (ROP) in preterm babies. It is one of the severe complications of prematurity. ROP is a vasoproliferative disorder of developing retinal vessels that affects premature infants and can lead to severe and irreversible visual impairment or blindness if left untreated. ROP remains among the leading causes of blindness in children today and it is now emerging as a very important cause of

blindness in children in middle-income countries in Latin America and Eastern Europe. Retinopathy is also increasingly reported in Asian countries, particularly in India and China, where it is likely to become an important cause of blindness in children, as these economies improve and services for the care of premature babies expand without proper monitoring of oxygen delivery. Approximately 1 of every 50 newborns in the United States will demonstrate ROP. Globally, an estimated third of surviving children with ROP requiring treatment (20,000; 95% CI 15,500 to 27,200) are severely visually impaired or blind secondary to ROP. One paper indicates that ROP contributed to 1.1% of all cases of blindness in children in Indonesia (Siswanto & Sauer 2017).

ROP-related blindness can be prevented by a multidisciplinary team approach, which includes obstetricians, neonatologists/paediatricians, nurses, ophthalmologists, health care workers, and parents. ROP stands a good example of all the strategies for prevention which includes primary prevention (prevention of the disease by improving obstetric and neonatal care), secondary prevention (screening and treatment programs for ROP) and tertiary prevention (treating complications and rehabilitation to reduce disability) (Kiranmayee & Kalluri 2019). This case reports the tertiary prevention (low vision examination and management) for a 5 years old boy with ROP-related blindness to use his remaining visual capacity to its fullest and be independent as possible to live a better life.

CASE REPORT

A 5 years old boy presented to our low vision clinic referred from Pediatric Ophthalmology division of Doctor Soetomo General Hospital with the provisional diagnosis of Left Eye Aphakic (history of anti-VEGF bevacizumab intravitreal injection and vitrectomy), Right Eye Retinopathy of Prematurity (ROP) stage 5 and Band Keratopathy. He had previous history of wearing eyeglasses +12.00 D on both eyes after left eye cataract extraction surgery in October 2019. He was born at 28 weeks of gestational age with birth weight 1600 grams in Bhakti Rahayu Hospital. He had received oxygen therapy and was admitted in neonatal intensive care unit at Bhakti Rahayu Hospital for a month. After that, patient was referred to Dr. Soetomo Hospital for ROP screening.

ROP was found in both eyes with the right eye was more severe than left eye. Unfortunately, his right eye was found ROP stage 5. Therefore, the secondary prevention to prevent ROP-related blindness had been

done in this patient to save his last eye. He had received anti-VEGF bevacizumab intravitreal injection and vitrectomy in his left eye at January 2015. Because of this history of intraocular procedure, complicated cataract was developed in his left eye. Simple aspiration cataract extraction surgery had been done in October 2019 and left aphakic. But a few months later, posterior capsule opacification (PCO) was developed. He had no similar history of visual loss in his other family members. His presenting visual acuity was light perception in RE and hand movement (with his +12.00 D spectacles) in LE. On binocular slit lamp examination, the anterior segment was found band keratopathy in RE, so it was difficult to evaluate structures after the cornea. In LE we found aphakic and PCO (Fig. 1). Fundus examination under mydriatics were difficult to be evaluated.

Low vision assessment

He was accompanied by his mother during the examination. He was a kindergarten student and will enter elementary school this year. His family tree suggests 2 siblings, he was the third child to his parents and rest of the children were apparently well. He had no previous history of low vision examination. He had problem with near vision task regarding difficulties in learning alphabets and numbers, but his mother said that he had known *hijaiyah* (Arabic) letters and recognized the picture. He suggested no any history of bumping into objects. He had no history of colour perception problem. He was comfortable in his daily living skills. His mother expectation that he would be able to read and attend class as a normal student.

His distance visual acuity was light perception in his right eye and 1/25 unaided in his left eye using Lea

Acuity Chart caused by difficulty recognizing numbers or letters. With his current eyeglasses (S+12.00), his distance visual acuity was 2/25 in his left eye. On objective retinoscopy, his refractive error was unable to evaluate in RE because of band keratopathy and S+14.00 D in LE with significant improvement in visual acuity in her both eyes. With S+14.00 D, his distance visual acuity become 3/40. His near vision was 10 M at 30 cm of reading distance unaided and 4M at 13 cm improving with spectacle + 3.00 D.

Binocularity assessment

The contrast sensitivity tested with Hiding Heidi chart was CS 80 (1.25%) at 3 meters which signifies good contrast sensitivity. The visual field as tested by confrontation test was within normal limit in his left eye and his right eye was not evaluated.

On trial of distance and near vision devices

Patient was prescribed high plus power +14.00 D new spectacle for distance vision. Patient's response was good, and his visual acuity improved significantly up to 3/40 using Lea Acuity Chart. He could walk independently. Patient's near vision also corrected with +3.00 D eyeglasses become 4 M at 13 cm of reading distance and he was comfortable reading with this eyeglasses.

The non-optical aids in this patient can be letter magnification, lighting, contrast (using the bigger marker), support for reading and writing (for example : book stand). For all of the optical aids (monofocal or bifocal spectacle prescription) and non-optical aids using. The important one is adaptation to use these instruments.

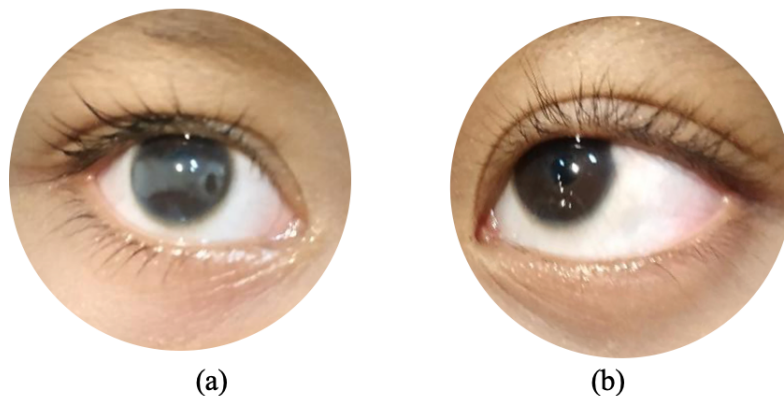


Fig. 1. Anterior Segment of Right Eye (a) and Left Eye (b).

The result of rehabilitation

Patient will perform for PCO, and secondary intraocular lens (IOL) implantation will be done at once when he is 8 years old, he suggested low vision management for this time while waiting for the next surgery. The patient was suggested to use optical devices such as bifocal eyeglasses prescription S+14.00 D for distance vision and S+3.00 D for near vision (could be separated or combined); Using non-optical devices (relative size magnification to help his learning process, such as large print books, enlarge homework assignments, low vision pen with bold tips); and Patient was asked to follow up every three months for low vision evaluation that the purpose is patient can be adaptation with the new instruments (optical and non-optical devices)

DISCUSSION

A low vision impairment in pediatric patient should be known by ophthalmologist that the impairment can affect motoric, cognitive and sensory that can impact intellectual, emotion and social. Every child with loss of vision needs to be recognized, and the ophthalmologist’s response should include recommending vision rehabilitation. Most adults with low vision have lost vision because of an ocular disease incurred later in life. Thus, they have already acquired many of the vision-aided skills that are important for functioning in society. Children with low vision, however, need to learn these skills despite poor or no vision (American Academy of Ophthalmology 2019). Low vision interferes with the ability to perform

everyday activities. Blind children are often discouraged and experience social and economic isolation. Many of these children have coexisting physical and/or cognitive disabilities that create further challenges to successful integration into society. It is a difficult task for the child and the family to cope up with the situation and start early intervention. In addition, skill acquisition is developmentally linked to vision, thus requiring different interventions at different ages. It is important to be aware of the needs of each age group and tailor the assistance to those needs (American Academy of Ophthalmology 2019, Kiranmayee & Kalluri 2019).

Low vision patients can improve their residual vision and possibly relearn to perform lost functional vision, which often restores the ability to perform daily tasks like reading. Rehabilitation of infants and children requires a team approach often involving pediatric ophthalmologists, vision rehabilitation clinicians, occupational therapists, teachers, orientation and mobility specialists, technology experts, state societies, and other professionals and organizations working with the child and family from the earliest stages possible. Ophthalmologists may be one of the most consistent contacts over many years for the parents of a visually impaired child, and, as such, they need to be aware of and support the rehabilitation process (American Academy of Ophthalmology 2016, Kiranmayee & Kalluri 2019). It was quite hard to find vision rehabilitation clinicians, occupational therapists and special educators in Indonesia. Thus, as an ophthalmologist, we have important role in rehabilitation process in order to achieve optimal visual performance.

Table 1. Classification of visual impairment according to the International Classification of Disease-10 2016 revision (Şahlı & İdil 2019)

Category	Presenting distance visual acuity	
	Worse than	Equal to or better than
- Mild or no visual impairment		6/18 3/10 (0.3) 20/70
- Moderate visual impairment	6/18 3/10 (0.3) 20/70	6/60 1/10 (0.1) 20/200
- Severe visual impairment	6/60 1/10 (0.1) 20/200	3/60 1/20 (0.05) 20/400
- Blindness	3/60 1/20 (0.05) 20/400	1/60* 1/50 (0.02) 5/300 (20/120)
- Blindness	1/60* 1/50 (0.02) 5/300 (20/120)	Light perception
- Blindness		

*or count fingers at 1 meter

Assessment in low vision depend on individual ability especially pediatric patient such as reading, playing. It can help the child perform to routine tasks in different material and places. The following are can be the test like distant and near visual acuity, lighting requirement, color perception, contrast sensitivity. Management of low vision in paediatric patient can be correction appropriate refraction, with prescription spectacle, anti-glare glasses, training to use a low vision devices, and telling to the family the prognosis improvement. The ophthalmologist should give the suggestion to parents about target illumination, choosing toys or games or visual reach activity.

Low vision devise can be the important one to improve visual performance in low vision rehabilitation. They are can be optical system or non-optical system and it can be magnification system also. Traditional options for magnification include higher adds, high-plus reading glasses, magnifiers, and telescopes. Other practical solutions to difficulties include modifying a task, such as by moving closer to distant targets; using larger formats, such as large-print checks; or substituting with audio, such as digital audio books available through libraries or online. There is increasing interest in devices such as e-readers, cell phones, computers and electronic magnification as excellent options for patients with low vision (American Academy of Ophthalmology 2019).

Optical aid devices used magnification principal, for example eyeglasses and telescope for distance vision. For this patient, eyeglasses was given as an optical aid device and the distance visual acuity could reach 3/40 and because of the lack of accommodation near vision correction (+3.00 Dioptri) can be added to improve his near acuity. This was very helpful in carrying out daily activities. Patient was not given telescope that greater magnification caused reduction in field of view, a narrow depth of field, reduced contrast and increase the level of difficulties in its use (American Academy of Ophthalmology 2019).

Non-optical aid devices also had an important role in low vision treatment ,that devices increase the patient's residual visual function or use signals that stimulate one of the other senses. Illumination, large-print books, increased contrast, typoscope, reading stands, and sunglasses or spectacles with filtering lenses to reduce glare can be used alone or in conjunction with optical systems in patients with low vision (Şahlı & İdil 2019). Illumination /lighting setting was important for patient with visual impairment, particularly decreased contrast sensitivity. The type of lighting that is optimal and position of the lamp must be arranged in such a way to minimize glare from the light that shines directly on the

patient's face or bounces off the page. The other device was electronic devices. Large screen monitor was very helpful in many cases. Software for screen magnification provided advanced utility to enlarge screen text and graphics and to integrate text-to-speech technology. Existing and future technologies, including e-readers, audio books, and text-to-speech technology, offer continually expanding opportunities for these children (American Academy of Ophthalmology 2019).

A variety of aids are available to assist patients with low vision, ranging from simple telescopes to Braille literacy. Because most children have large accommodative amplitudes that allow them to hold an object closer than normal to enlarge its image, magnifiers may not be necessary for pediatric patients with low vision. The child's need at home and in school setting must be considered as well (American Academy of Ophthalmology 2016). It is also very important to modify the patient's living conditions. Taking measures such as sitting students in the middle of the front row of the classroom, organizing the kitchen or other environments in a contrasting and appropriate way, and accentuating steps and handrails will make daily life easier. Low vision rehabilitation is not just the prescription of a low vision aid. Training programs consisting of habituation exercises practiced in the clinic or at home constitute one of the most important stages of rehabilitation (Şahlı & İdil 2019). Visual impairment caused by ROP is not an easy thing to deal with, but low vision rehabilitation and the use of optical and non-optical aid devices can improve functional status and quality of life of patient. By using component of low vision devise can activate his requirement of knowledge by reading alphabets and numbers, and others vision-aided skills like learn doing daily activity independently as possible to grow while waiting for further surgical management.

CONCLUSION

ROP blindness is largely preventable if appropriate, adequate and accessible screening programmes are available. Unfortunately, even with the current screening guidelines and recommended treatment of ROP, many babies are blinded by this disease each year. Although this patient was classified as blindness based on his best corrected visual acuity, he still needed low vision management and rehabilitation because his left eye's visual function could be better than this time after the next surgery. He needed to learn as much as possible in this age using his remaining visual capacity. Spectacle prescription for distance vision, customized larger print textbook to facilitate him learning alphabets and numbers, used low vision pen with bold tips to learn

writing and optimal illumination were able to improve his distance and near vision and can help the learning process. This low vision temporary management was expected to help the patient learn meaningful skills for his life while waiting further surgical management.

REFERENCES

- American Academy of Ophthalmology (2019). *Clinical optics*, 2019th-2020th ed, Basic and clinical science course. San Francisco, California
- American Academy of Ophthalmology (Ed.) (2016). *Pediatric ophthalmology and strabismus*, 2016th-2017th ed, Basic and clinical science course. San Francisco, California
- Fontenot JL, Bona MD, Kaleem MA, et al (2018). Vision Rehabilitation Preferred Practice Pattern. *Ophthalmology* 125, P228-P278
- Kiranmayee P, Kalluri V (2019). India to gear up to the challenge of third epidemic of retinopathy of prematurity in the world. *Indian J Ophthalmol* 67, 726. https://doi.org/10.4103/ijo.IJO_700_18
- Şahlı E, İdil A (2019). A common approach to low vision: examination and rehabilitation of the patient with low vision. *Turkish journal of ophthalmology* 49, 89–98
- Shah P, Schwartz SG, Gartner S, Scott IU, Flynn HW (2018). Low vision services: a practical guide for the clinician. *Ophthalmol Eye Dis* 10, 251584141877626. <https://doi.org/10.1177/2515841418776264>
- Siswanto J, Sauer PJ (2017). Retinopathy of prematurity in Indonesia: Incidence and risk factors. *NPM* 10, 85-90. <https://doi.org/10.3233/NPM-915142>