

## **Postpartum Coccydynia: an Anatomy Overview**

<sup>1</sup>Reza Maulana, <sup>2</sup>Nur Wahyuniati, and <sup>3\*</sup>Imai Indra

<sup>1</sup>Department of Anatomy Histology, Medical Faculty, Syiah Kuala University, Darussalam, Banda Aceh 23111, Indonesia;

<sup>2</sup>Department of Parasitology, Medical Faculty, Syiah Kuala University, Banda Aceh 23111, Indonesia;

<sup>3</sup>Department of anesthesiology, Medical Faculty, Syiah Kuala University, Banda Aceh 23111, Indonesia;

\*Corresponding Author: imai\_indra@yahoo.com

### **Abstract**

Coccydynia is a term that refers to a painful condition in and around the coccyx. This symptom is typically a discomfort or pain which is felt when sitting for long time and when rising from sitting position. Many physiologic and psychological factors contribute to its etiology, but the majority of cases were found to be aggravated by pregnancy and childbirth (postpartum). Luxation and fracture of the coccyx are the two most common lesion of postpartum coccydynia. This poster shows an anatomy overview especially the coccyx to increase the understanding about this symptom.

**Key words:** coccydynia, coccyx, anatomy

### **Introduction**

Coccydynia is a term that refers to a painful condition in and around the coccyx. This symptom is typically a discomfort or pain which is felt when sitting for long time and when rising from sitting position, it may be worsened with other hip extension activities such as stair climbing. It may affect all ages and gender, but the prevalence is five times greater in women than in men.

Many physiologic and psychological factors contribute to its etiology, such as local injury and some pathologies include perineural cysts, chordoma, giant cell tumor, intra osseous lipoma, intradural schwannoma, referred pain from lumbosacral disc prolapse and some other often labeled as idiopathic. The majority of cases were found to be aggravated by pregnancy and childbirth (postpartum). In postpartum coccydynia there was no free interval between childbirth and occurrence of the pain. It appeared very soon after the childbirth, as soon as the sitting position adopted.

During pregnancy, the coccyx will be relaxed and loosened to facilitate childbirth; this condition may sometimes result in coccygeal pain or coccygeal injury. During vaginal delivery the sacrococcygeal ligaments may be damaged, and the acute trauma of the coccyx may appear during the passage of the fetus through birth canal. An intrapartum coccygeal fracture or dislocation also supposed to be the cause for postpartum coccydynia. Various numbers of managements has been discovered to treat coccydynia, which is consists of non-operative management and operative management. An inadequate understanding of the coccyx region lead to inadequate understanding of postpartum coccydynia's etiology, and it may affect the management needed.

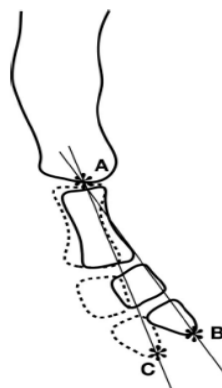### **Materials and Methods**

All images contained in this poster are the result of a number of articles search. Figure 1 and 2 using illustrations or sketches to explain the movement of the coccyx and the anatomic signs of coccydynia, this technique is used for a better understanding of normal and abnormal movement direction of the coccyx (Woon, 2012; Fogel, 2004). Figure 3 and 4 using a real radiographic picture to explain the posterior subluxation and a fracture of coccyx, this technique is used for a better understanding about the coccyx abnormality during standing and sitting position (Maigne, 2012).

### **Results and Discussion**

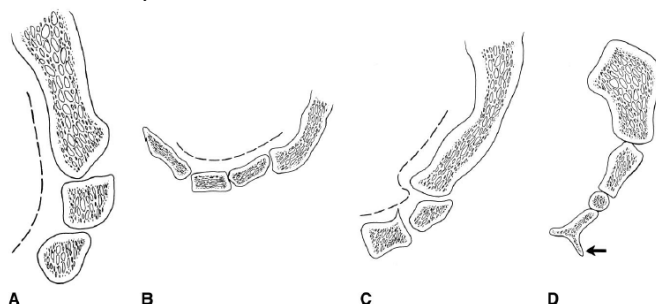
The coccyx (kok'siks), or tailbone, is a triangular shape bone which is the lowest part of the vertebral column and is usually composed of 3 to 5 fused vertebrae segments. The coccyx being an attachment site for various muscles, it serves as a weight-bearing structure when a person is seated, thus completing the tripod of weight bearing composed of the coccyx and the bilateral ischium. There are extensive variabilities in the structure of the joints, such as: intact discs resembling lumbar

intervertebral discs to intermediate disc structures with cystic or fibrotic changes to synovial joints. In some cases, the joints are fused together.

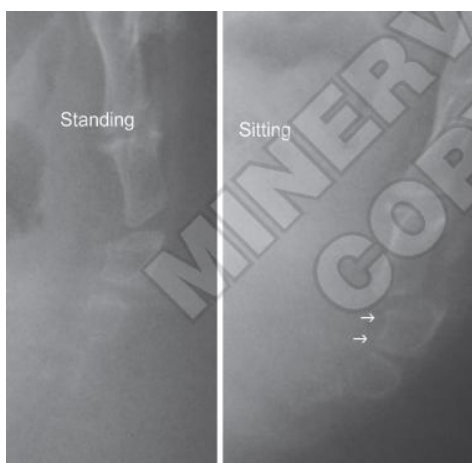


**Figure 1.** Range of motion of the coccyx. The apex of the angle in the standing (bold line, B) and sitting (dotted line,C) positions is at the mid - sacrococcygeal joint (Woon, 2012).

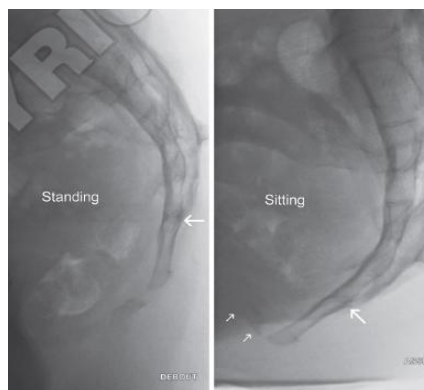
Certain types of coccygeal morphology also can lead to a predisposition to coccydynia. Patients with a sharp ventral angulation of the coccyx are considered more at risk of developing coccydynia. Postpartum coccydynia is frequently associated with the use of forceps during childbirth. Women with a "short perineum" (a value determined by measuring the distance between the fourchette and the tip of the coccyx on one hand and the anus on the other) may have a higher risk of coccyx injury during childbirth. There are two most characteristic lesion of postpartum coccydynia: luxation that occurs in sitting position and fracture of coccyx.



**Figure 2.** The anatomic signs of coccydynia: A. Normal standing appearance of the coccyx; B. Increased flexion mobility of the coccyx when patient is seated; C. Posterior subluxation of the coccyx when patient is seated; D. Coccygeal spicule (arrow) arising from the dorsal surface of coccygeal segment (Fogel, 2004).



**Figure 3.** Posterior subluxation of the first intercoccygeal joint. The standing radiography is normal. In the seated position the coccyx moves rearwards (Maigne, 2012).



**Figure 4.** Fracture of the coccyx. Occured in an ossified and rigid coccyx (bold arrow: fused sacrococcygeal joint). This is a pseudoarthrosis with marked mobility during the transition to a seated position (double arrow).

### Conclusions

Postpartum coccydynia appears to be associated with difficult deliveries. Luxation and fracture of the coccyx are the two most common lesion of postpartum coccydynia. It is surprising that postpartum coccydynia had not been studied widely. Further advance research is needed to provide better knowledge of coccyx region and its relationship with postpartum coccydynia.

### Acknowledgements

We thank Dr. dr. Endang Mutiawati R, Sp.S (K) the Vice Dean for Academic affair of Medical Faculty Syiah Kuala University for encouraging the submission of this poster to international scientific event.

### References

- Lirette, L.S. (2014). Coccydynia: An overview of the anatomy, etiology, and treatment of coccyx pain. *The Ochsner journal*, 14: 84-87.
- Patel, R., A. Appannagari, and P.G. Whang. (2008). Coccydynia. *Curr Rev Musculoskeletal Med*, 1: 223-226.
- El-Mekawy, H.S., A.B. Nashed and M.S. Moursi. (2000). Efficacy of ultrasonic therapy in treating post partum coccydynia following vaginal delivery. *Bull. Fac. Ph. Th. Cairo Univ*, 11(2).
- Fogel, G.R., P.Y.C. III, and S.I. Essess. (2004). Coccygodynia: evaluation and management. *J Am Acad Orthop Surg*, 12: 49-54.
- Wray, C.C., S. Easom, and J. Hoskinson. (1991). Coccydynia, aetiology and treatment. *J Bone Joint Surg*, 73-B: 335-8.
- Maigne, J.-Y., F. Rusakiewicz, and M. Diouf. (2012). Postpartum coccydynia: a case series study of 57 women. *Eur J Phys Rehabil Med*, 48: 387-92.
- Kaushal R. (2005). Intrapartum coccygeal fracture, a cause for postpartum coccydynia: a case report. *Journal of surgical orthopaedic advances*, 14(3): 136-7.
- Shier, D., J. Butler, and R. Lewis. (2012). *Hole's essentials of human anatomy and physiology*, 11th ed. McGraw-Hill Companies, Inc., New York.
- Woon, J.T.K. and M.D. Stringer. (2012). Clinical anatomy of the coccyx: a systematic review. *Clinical anatomy*, 25: 158-167.