

## A 44-DAY OLD MALE INFANT WITH THORACOABDOMINAL ECTOPIA CORDIS OF PENTALOGY CANTRELL'S SYNDROME

Tri Yuliantini<sup>1</sup>, Eka Gunawijaya<sup>1</sup>, Ketut Putu Yasa<sup>2</sup>

Departments of Child Health<sup>1</sup> and Thoracic Surgery<sup>2</sup> Medical School Udayana University/  
Sanglah Hospital Denpasar

### ABSTRACT

Ectopia cordis is a rare and impressive congenital abnormality, occurring in 5.5 to 7.9 per 1 million live births. The defect is characterized by partial or complete displacement of the heart out of the thoracic cavity. This defect require a staged procedure to achieve a complete repair. We reported a 44-day-old male infant presented with symptoms of tachypnea and mild cyanosis since birth. On physical examination, the child looked lethargic with a weak cry. The midline defect extended from the lower margin of the neck to the umbilicus. The sternum was completely bifid, with an inter-ridge distance of 6 cm, through which the heart was protruded for 4-5 cm and the apex pointed anteriorly. The first and second heart sounds were normal with ejection holosystolic murmur. The diagnosis was ectopia cordis. A two dimensional echocardiography showed complete atrioventricular septal defect, which was known as a group of cyanotic congenital heart defect. The infant was referred subsequently to the neonatal intensive care unit with the ventilator support. Historically, the prognosis of this condition is poor. Our patient died before surgery being performed. [MEDICINA 2013;44:50-55]

*Keywords:* ectopia cordis, congenital heart defects

## BAYI USIA 44 HARI DENGAN EKTOPIK KORDIS TIPE TORAKOABDOMINAL PADA PENTALOGY SINDROM CANTRELL'S

Tri Yuliantini<sup>1</sup>, Eka Gunawijaya<sup>1</sup>, Ketut Putu Yasa<sup>2</sup>

Bagian/SMF Ilmu Kesehatan Anak<sup>1</sup> dan Bedah Toraks Kardiovaskular<sup>2</sup>  
Fakultas Kedokteran Universitas Udayana/Rumah Sakit Umum Pusat Sanglah Denpasar

### ABSTRAK

Ektopik kordis merupakan suatu kelainan bawaan yang langka, terjadi pada 5,5 sampai 7,9 per 1 juta kelahiran hidup. Kelainan ini ditandai menonjol sebagian ataupun keseluruhan jantung ke luar dari rongga dada. Penanganan ektopik kordis memerlukan beberapa tahapan prosedur tindakan pembedahan. Kami melaporkan seorang bayi laki laki berusia 44 hari dengan gejala takipne dan sianosis sejak lahir, tampak letargi dan menangis lemah. Terdapat defek sepanjang sternum dari batas bawah leher hingga umbilikus dengan sternum yang terbelah dengan jarak 6 cm. Jantung menonjol ke luar rongga dada sejauh 4-5 cm dengan apeks jantung di bagian anterior. Suara jantung satu dan dua normal dengan murmur ejeksi holosistolik. Penderita didiagnosis ektopik kordis dan disertai penyakit jantung bawaan sianotik berupa komplisit defek septum arterioventrikuler yang didapatkan dari pemeriksaan ekokardiografi. Pasien dirawat di ruang intensif selama 5 hari dengan bantuan ventilator. Prognosis pasien dengan ektopik kordis adalah buruk. Pasien kami meninggal sebelum sempat dilakukan pembedahan. [MEDICINA 2013;44:50-55]

*Kata kunci:* ektopik kordis, kelainan jantung bawaan

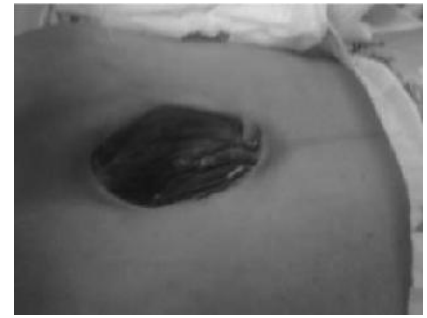## INTRODUCTION

Ectopia cordis is a rare and impressive congenital abnormality, occurring in 5.5 to 7.9 per 1 million live births.<sup>1</sup> The defect is characterized by partial or complete displacement of the heart out of the thoracic cavity. This anomaly is classified into five types: cervical, cervicothoracic, thoracic, abdominal, and thoracoabdominal.<sup>2</sup> The two most common forms of ectopia cordis are the thoracic and thoracoabdominal type.<sup>3,4</sup> The latter is frequently associated with Cantrell's pentalogy, which include bifid sternum, deficiency of the diaphragm, defect of diaphragmatic pericardium, defect of the anterior abdominal wall, and intracardiac defects.<sup>3,5</sup> Previous reports suggest a poor prognosis for patients with ectopia cordis, particularly in the presence of thoracic ectopia cordis and significant heart defects.<sup>1</sup> More recently, with the advances in the medical field and surgical techniques, more patients born with this medical condition have been successfully treated and have survived. In general, the goal of the initial management is directed at providing coverage of the bare heart with skin or synthetic material without causing hemodynamic embarrassment. Later, subsequent operations to repair the intracardiac defects and to reconstruct the chest wall can be done.<sup>6</sup> In this report, we present a case of thoracoabdominal ectopia cordis and an overview of its management in the medical literature.

## CASE REPORT

Forty four days old male infant was referred from Mataram Hospital, West Nusa Tenggara on March 28<sup>th</sup> 2011. He was complained has a heart outside his chest wall since birth, his heart only covered by a thin reddish layer without any skin nor a sternum. He was complained with continuous tachypneu and circumoral cyanosis since birth. During pregnancy, his mother had never attended any antenatal care, no fetal ultrasonography, no history of drug abuse nor consanguinity. Labour history found no premature ruptured of membrane, he was born vigorously with APGAR scores of 7-9 and birth weight was 3300g.

On physical examination, the baby looked lethargic with a weak cry. He had no pallor nor jaundice but had acrocyanosis. The pulse on extremity was regular and adequate. The midline defect extended from the lower part of sternum to umbilicus. The sternum was completely bifid, with an inter-ridge distance of 6 cm, through which the heart was protruded for 4-5 cm and the apex pointed anteriorly. The first and second heart sounds were normal with holosystolic ejection murmur. The breath sounds were normal and there were no additional sounds on chest auscultation. Central nervous system was normal. There was no cleft lip or palate. Based on clinical feature, the diagnosis of ectopia cordis was made (**Figure 1**).



**Figure 1.** Ectopia cordis.

We did some investigations such as complete haemograms, electrolytes, blood gas analysis, blood sugar, C-Reactive Protein (CRP), blood culture, prothrombin time (PT)/activated partial thromboplastin time (APTT), chest X-ray and echocardiography. Consultations to various specialists including pediatric cardiologists, cardiothoracic surgeons, anesthetists, and the intensivists were done, and the patient was started on prophylactic antibiotics (cefotaxime 100 mg/kg/day every 8 hours). The complete blood count investigation revealed haemoglobin was 15.4 g/dL, white blood cells count 13.3 K/uL, platelets count 335 K/uL, sodium 134.6 mmol/L, potassium 6.151 mmol/L, chloride 103.4 mmol/L, calcium 19.26 mg/dL, CRP 0.50, PT 14 second, APTT 65.5 second, INR 1.2. Blood gas analysis showed pH 7.30, pCO<sub>2</sub> 56 mmHg, pO<sub>2</sub> 54 mmHg, HCO<sub>3</sub> 27.6 mmol/L, BE 0.10 mol/L, SatO<sub>2</sub> 84%. The chest X-ray showed complete absence of sternum, normal pulmonary vascular markings and a midline chest deformity, no cardiomegaly seen cardiothoracic ratio 56%, the apex was in left midclavicular line, intercostal space VII

(Figure 2). A two dimensional echocardiography showed atrial situs solitus, a primum large atrial septal defect (ASD), large inlet to outlet ventricular septal defect (VSD) (8.3 mm), common arteriovalvular (AV) valve. The conclusion of echocardiography was complete atrioventricular septal defect (AVSD), which was known as a group of cyanotic congenital heart defect (CHD) (Figure 3).

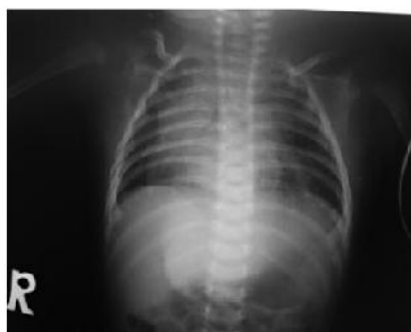

Figure 2. Chest - ray showed complete absence of sternum, normal pulmonary vascular markings and a midline chest deformity, cardiothoracic ratio 56%.

The newborn was referred subsequently to the neonatal intensive care unit. Nutritional support was provided with parenteral nutrition and nasogastric tube feeding. Upon admission, the baby was commenced on 10% dextrose, with supplemental sodium and potassium and placed in incubator. Continuous percutaneous oxygen saturation was monitored. Supplemental oxygen (100%) was given by oxyhood at 15 L/min. The heart was covered with sterile gauze moister with normal saline and changed every four hours. Surgical repair of thoracoabdominal ectopia cordis was planned thereafter.

On the fifth day of admission the baby developed

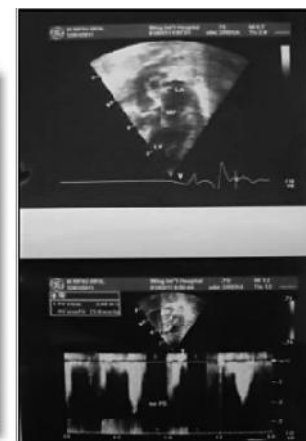
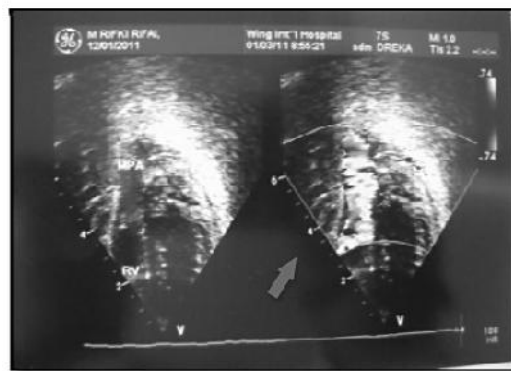
Figure 3. A two dimensional echocardiography showed complete atrioventricular septal defect. (AVSD).

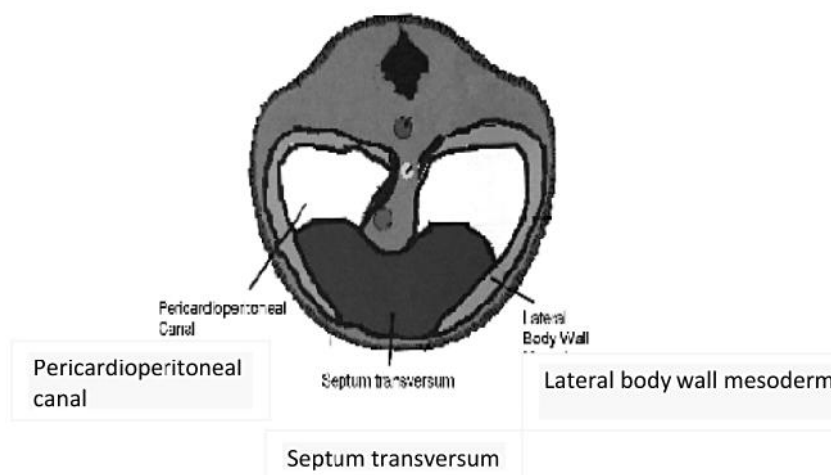


Figure 4. Body cavity development showing early pericardial cavity.

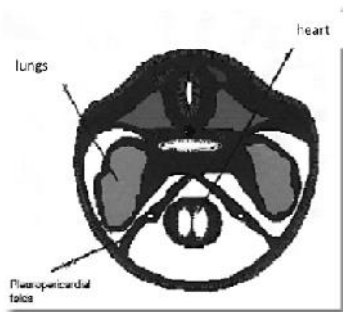
sclerema, the saturations started to fall. He had episodes of hypothermia and followed by abdominal distended so enteral feeding was stopped. His total neutrophil count increased to 16.6 K/uL with decreasing pO<sub>2</sub> 53 mmHg and increasing pCO<sub>2</sub> 75 mmHg. The infant became deteriorated. He required assisted ventilation for 3 days. The baby was dead after resuscitation because of heart failure.

### DISCUSSION

During the third week of gestational life, when

the demarcation between the intraembryonic and extraembryonic coeloms is established, development of the body cavities and diaphragms begins. By the beginning of the fourth week, a horseshoeshaped cavity develops in the cardiogenic and lateral mesoderms (Figure 4). The curve of the horseshoe represents the future pericardial cavity. During this period, the pericardial and peritoneal cavities communicate dorsally through the pericardioperitoneal canals. Caudally, the developing septum transversum will

ultimately separate the thoracic and abdominal cavities by formation of the diaphragms. The fibrous pericardium forms from the pleuropericardial folds. The folds grow toward the midline and attach to the primitive mediastinum and end up separating the heart from the lungs, with the thoracic cavity now divided into a pericardial cavity and two pleural cavities (Figure 5). During folding of the embryonic disc in week 4, the lateral body walls converge together on the ventral aspect of the embryo and fuse. It is at this stage that incomplete fusion may occur and result in the partial or complete evisceration of the heart through the defect. The etiology of this process is unknown. The embryological development of this anomaly may be related to early fetal rupture of the amnion, chorion, or yolk sac, as well as teratogens, or chromosomal aberrations.<sup>7</sup>



Pleuropericardial folds

**Figure 5.** Body cavity development showing formation of pleuropericardial folds.

The pentalogy of Cantrell is a rare syndrome with an estimated incidence of 5.5 per 1 million live births.<sup>8</sup> It is described as a deficiency of the anterior diaphragm, a midline supraumbilical abdominal wall defect, a defect in the

diaphragmatic pericardium, various congenital intracardiac abnormalities, and a defect of the lower sternum. The pathogenesis of pentalogy of Cantrell has not been fully elucidated. Ectopia cordis itself is described as malposition of the heart, partially or completely outside the thorax.<sup>8</sup> Ectopia cordis is rarely associated with chromosomal abnormalities. According to the position of the misplaced heart, ectopia cordis can be classified into five types: 1) cervical, in which the heart is located in the neck with sternum that is usually intact; 2) thoracocervical, in which the heart is partially in the cervical region but the upper portion of the sternum is split; 3) thoracic, in which the sternum is completely split or absent, and the heart lies partially or completely outside the thorax; 4) thoraco-abdominal, which usually accompanies Cantrell's syndrome; 5) abdominal, in which the heart passes through a defect in the diaphragm to enter the abdominal cavity.<sup>2,6</sup> In our case, we found thoracoabdominal type of ectopia cordis with a predominant thoracic component.

The majority of ectopia cordis patients have associated intracardiac defects. Ventricular septal defect, atrial septal defect, tetralogy of Fallot, and diverticulum of the ventricle are the most commonly encountered heart lesions.<sup>3,9</sup> The severity and the complexity of the intracardiac defect contribute largely to the poor prognosis associated with this malformation.<sup>3</sup> In our case,

there were completely bifid sternum, anterior extrathoracic heart with complete AVSD.

Ectopia cordis has also been reported with other congenital anomalies such as abdominal wall defects, cranial and facial malformations, cleft lip and palate, anencephaly, hydrocephaly, neural tube defects, pulmonary hypoplasia, genitourinary malformation, gastrointestinal defect, and chromosomal abnormalities.<sup>1,4,10</sup> In our case, there were no other congenital anomalies, except it.

If the diagnosis of ectopia cordis is confirmed during the pregnancy, an early plan should be made for elective atraumatic cesarean delivery.<sup>10</sup> Immediately after birth, the newborn should be stabilized and the lesion should be covered with saline-soaked gauze pads and wrapping to prevent desiccation and heat loss of the exposed viscera.<sup>4</sup> After completing the preoperative evaluation, the patient should be taken promptly to the operation room for surgical repair of the defects. The managements of ectopia cordis are: closure of the chest wall defect, including the sternal defect, repair of the associated omphalocele, placement of the heart into the thorax, and repair of the intracardiac defect.<sup>6,9</sup> Unfortunately, in most of the cases the thoracic cavity is small, and the mediastinum offers too little space for the heart. Attempts to close the chest wall after replacing the heart into the thoracic cavity often result in intolerable hemodynamic embarrassment secondary to kinking of the

great vessels or compression of the heart muscle.<sup>1,6</sup> Therefore, a staged repair often times is a necessary approach to correct this anomaly. The first priority is to obtain coverage of the exposed heart. This can be accomplished in some cases by mobilizing the skin over the chest wall and directly closing the skin. If this manouver seems to cause hemodynamic instability, then either a skin grafting or prosthetic patch should be considered.<sup>6,11</sup> In our case, the mother never attended any antenatal clii so we could not confirmed the diagnosis during the pregnancy, and we could not do the surgical procedure because of the instability of the patient's condition. The surgeon planned to do the suturing of the skin to skin above the defect.

Some other techniques to repair the chest defect have been described in the medical literature. In one report, the authors illustrated the use of bilateral pectoralis major and rectus abdominis mucocutaneous flaps to repair thoracoabdominal ectopia cordis.<sup>4</sup> Another report described an attempt to do onestage repair of ectopia cordis immediately after birth using transected ribs to reconstruct the thorax.<sup>13</sup> The potential advantages of staged repair are to minimize the compression of the heart and the big vessel, and to allow the thoracic cavity to expand gradually.

After a successful first-stage operation to provide coverage of the heart, the subsequent operations aim to repair the intracardiac defect

and to reconstruct the chest wall. In most of the reported cases, the intracardiac defect repair was performed after the first stage operation.<sup>1</sup> Nevertheless, if the intracardiac defect is "simple" and amenable to immediate surgical correction, it might be legitimate to repair it during the initial stage operation. In a case published in 1973, a repair of thoracoabdominal ectopia cordis and ventricular diverticulum was achieved successfully in a one-stage operation with the use of cardiopulmonary bypass.<sup>12</sup> More recently, an attempt repair a double-outlet right ventricle and complete thoracic ectopia cordis was done in a single-stage operation immediately after birth. The newborn survived 12 days after surgery but finally died from sepsis.<sup>13</sup> As the child grows, it becomes indicated to reconstruct the chest wall for protective and cosmetic reasons. Autologous rib grafts have been used with success to reform a bony thorax.<sup>6</sup> This method is safe and reliable particularly if the amount of the native ribs is sufficient enough for graft donation without compromising the integrity of the patient's chest wall.<sup>2</sup> Another alternative is to use alloplastic materials to close the sternal defect and to reconstruct the chest wall. Unlike the initial first-stage repair of the chest that needs to be done soon after birth, the second-stage surgery to reconstruct the chest wall is an elective procedure usually done after the first year of life.<sup>2,6</sup> In our case, we could not do the surgical procedure because of

the instability of the patient's condition and the lack of CFB machine for baby in Sanglah Hospital.

Congestive heart failure occurred possibility related to complete AVSD without protecting pulmonary blood flow (without pulmonary stenosis).<sup>14</sup> In our case, it may result a congestive heart failure making the cardiac problem become more complex that anatomical defect accompanied with functional cardiac problem.

## SUMMARY

We reported a 44-day-old male infant presented with symptoms of tachypnea and mild cyanosis since birth. On physical examination, the child looked lethargic with a weak cry. The midline defect extended from the lower margin of the neck to the umbilicus. The sternum was completely bifid, with an inter-ridge distance of 6 cm, through which the heart was protruded for 4-5 cm and the apex pointed anteriorly. The first and second heart sounds were normal with ejection holosystolic murmur. The diagnosis was ectopia cordis. A two dimensional echocardiography showed complete atrioventricular septal defect, which was known as a group of cyanotic congenital heart defect. The infant was referred subsequently to the neonatal intensive care unit with the ventilator support. Historically, the prognosis of this condition is poor. Our patient died before surgery being performed.

## REFERENCES

1. Hornberger LK, Colan SD, Lock JE, Wessel DL, Mayer JE. Outcome of patients with ectopia cordis and significant intracardiac defects. *Circulation*. 1996;94:32-7.
2. Kim KA, Vincent WR, Muenchow SK, Wells WJ, Downes SE. Successful repair of ectopia cordis using alloplastic materials. *AnnPlastSurg*. 1997;38:518-22.
3. Amato JJ, Zelen J, Talwakar NG. Single stage repair of thoracic ectopia cordis. *Ann Thorac Surg*. 1995;59:518-20.
4. Hochberg J, Ardenghy MF, Gustafson RA, Murray GF. Repair of thoracoabdominal ectopia cordis with mucocutaneous flaps and intraoperative tissue expansion. *Plast Reconstr Surg*. 1995;95:148-51.
5. Abdallah HI, Marka LA, Balsara RK, Davis DA, Russo PA. Staged repair of pentalogy of Cantrell with tetralogy of Fallot. *Ann Thorac Surg*. 1993;56:979-80.
6. Dobell AR, William HB, Long RW. Staged repair of ectopia cordis. *J Ped Surg*. 1982;17:353-8.
7. Hill DS. First-Trimester ectopic cordis in a twin gestation, using 3D surface rendering and reconstruction. *JDMS*. 2005;21:420-3.
8. Taussing HB. World survey of the common cardiac malformation: developmental error of genetic variant. *Am J Cardiol*. 1982;50:544-59.
9. Geva T, Van-Praagh S, Van-Praagh R. Thoracoabdominal ectopia cordis with isolated infundibular atresia. *Am J Cardiol*. 1990;66:891-3.
10. Leca F, Thibert N, Khoury W, Fermont L, Laborde F, Dumez Y. Extrathoracic heart (ectopia cordis): report of two cases and review of literature. *Int J Cardiol*. 1989;22:221-8.
11. Diaz JH. Perioperative management of neonatal ectopia cordis: report of three cases. *Anest Analg*. 1992;75:833-7.
12. Morello M, Quaini E, Nenov G, Pome G. Extrathoracic ectopia cordis. *J Cardiovasc Surg (Torino)*. 1994;35:511-5.
13. Symbas PN, Ware RE. A syndrome of defects of thoraco-abdominal wall, diaphragm, pericardium and heart. One stage surgical repair and analysis of the syndrome. *J Thorac Cardiovasc Surg*. 1973;65:914-9.
14. Watterson KG, Willinksor JL, Kliman L, Mee RB. Complete thoracic ectopia with double outlet right ventricle: neonatal repair. *Ann Thorac Surg*. 1992;53:146-7.