

TYPE IC CHOLEDOCHAL CYST PRESENTING AN EXTRAHEPATAL CHOLESTASIS IN A 3 YEAR OLD BOY

Muhammad Reza¹, Nyoman Metriani Nesa¹, I Gusti Ngurah Sanjaya Putra¹,
I Putu Gede Karyana¹, Made Darmajaya²

*Departments of Child Health¹ and Paediatric Surgery², Udayana University
Medical School / Sanglah Hospital Denpasar Bali*

ABSTRACT

Choledochal cyst is a rare congenital dilatation of the bile ducts, mostly diagnosed in childhood. When appropriate resection is not performed, cholangiocarcinoma may occur in a high incidence within the second decade of life. This report aims to present a rare case in experience of diagnosis and management type IC choledochal cyst in children. We present case of a 3-year-old boy who came with jaundice and itchy skin, abdominal pain, brownish urine, pales colored of stool. Abdominal ultrasonography and computed tomography scan revealed type IC choledochal cyst. Patient underwent complete cyst removal surgery and bilioenteric anastomosis through Roux-en-y hepaticojejunostomy. Excision biopsy confirmed the diagnosis of type IC choledochal cyst. Post surgical follow up shown good physical and laboratory condition and there was no recurrence of symptoms. Early surgical procedure through Roux-en-y hepatojejunostomy, has been performed. Long term follow up also facilities good prognostic to the patient. [MEDICINA 2015;46:56-60].

Keywords: choledochal cyst, children, surgery

KISTA KOLEDOKAL TIPE IC PENYEBAB KOLESTASIS EKSTRAHEPATAL PADA ANAK LAKI-LAKI UMUR 3 TAHUN

Muhammad Reza¹, Nyoman Metriani Nesa¹, I Gusti Ngurah Sanjaya Putra¹,
I Putu Gede Karyana¹, Made Darmajaya²

*Bagian / SMF Ilmu Kesehatan Anak¹ dan Bedah Anak², Fakultas Kedokteran
Universitas Udayana / Rumah Sakit Umum Pusat Sanglah Denpasar Bali*

ABSTRAK

Kista koledokus adalah merupakan penyakit saluran empedu bawaan yang jarang dijumpai dan banyak terdiagnosis pada saat usia anak-anak. Tindakan berupa reseksi kista adalah yang terpenting dilakukan, jika tidak segera dilakukan maka dapat meningkatkan resiko terjadinya *cholangiocarcinoma* dalam usia dekade kedua penderita dalam kehidupan. Tujuan kasus ini dilaporkan untuk menggambarkan pengalaman dalam mendiagnosis dan tata laksana kista koledokal tipe IC yang jarang pada anak-anak. Laporan kasus ini pada anak laki-laki berumur 3 tahun dengan keluhan kulit tampak kuning dan gatal, nyeri perut, urin berwarna kecoklatan, tinja yang pucat. Ultrasonografi dan *CT scan* abdomen memperlihatkan adanya kista koledokus. Tindakan bedah eksisi kista dan anastomosis bilioenterik dengan menggunakan teknik hepatojejunostomi *Roux-en-y*. Diagnosa kista koledokus tipe IC terkonfirmasi saat tindakan eksisi biopsi. Evaluasi setelah dilakukan tindakan bedah memperlihatkan hasil yang bagus, baik dari pemeriksaan fisik maupun pemeriksaan penunjang dan hilangnya keluhan yang ada sebelumnya. Walaupun prosedur tindakan hepatojejunostomi *Roux-en-y* secara dini telah dilakukan, penderita masih membutuhkan evaluasi dalam jangka waktu yang lama. [MEDICINA 2015;46:56-60].

Kata kunci: kista koledokus, anak-anak, bedah

INTRODUCTION

Choledochal cyst is a rare congenital dilatation of the bile ducts. The estimated incidence in Western countries varies between 1 in 100,000 and 1 in 150,000. The incidence is 1 in

1000 in Asian population, of which about two third cases are reported from Japan.¹ Choledochal cysts are usually diagnosed in childhood and about 25% are detected in adult life.² Choledochal cysts also have an unexplained female and male preponderance, commonly reported

as 4:1 to 3:1. Choledochal cyst are classified based on the location of biliary duct dilation as described and modified by Todani, et al.³

The classic triad of symptoms includes abdominal pain, palpable abdominal mass, and jaundice, are seen in less than 20% of cases. An

85% of children have at least 2 features of classic triad, whereas only 25% of adults present with at least 2 features of the classic triad. Neonates who has been detected antenatally are usually asymptomatic at birth but need to be intervened early before the onset of complications.^{1,2} Complications of choledochal cyst include pancreatitis, cholangitis, secondary biliary cirrhosis, spontaneous rupture of cyst, and cholangiocarcinoma. Improved imaging modalities have facilitated the diagnosis at any time from antenatal to adult life.^{4,5}

Surgical management has evolved from cystenterostomy, which was associated with recurrence of symptoms and malignancy to primary cyst excision with Roux-en-Y bilioenteric drainage either open or laparoscopic. In a few type such as in IVA and V type choledochal cyst patients may need hepatic resection or liver transplantation.^{4,5}

The purpose of this report was to present our diagnosis and management experience in a rare case of type IC choledochal cyst in children, attempting to elucidate a surgical treatment is the main therapy.

CASE ILLUSTRATION

A 3 year old boy was brought by parents to Sanglah Hospital Outpatient clinics on April 4th 2014 with chief complaint yellowish color of skin which started five days before admission to the hospital. It started from palms and extended to whole body followed by itchy skin, in the next two days, eyes of this patient were also getting jaundice. Patient also experienced abdominal pain especially on upper part. Although the pain was not always perceived but it was sub sequentially getting worse especially after meal. He also complained brownish urine appearance and pale color of stool since three days before hospitalization. No fever noted.

There were no history of previous hepatobiliary disorders, routine medication or hospitalization since birth. There was no familial history of recurrent cholestasis nor jaundice.

The patient was the second child in the family. He was born full term at hospital, spontaneously, birth weight of 3.100 grams and healthy condition and breast fed for a year. The immunization record was complete according to the government recommendation. His food recall was in accordance to recommended daily allowance (RDA). The patient never had a blood transfusion history.

During physical examination, the patient was alert and the vital sign was normal. According to WHO 2006 growth chart, the patient was well nourished. Developmental stages was also normal. There was no dysmorphic face, no pale conjunctivas. Sclera were yellowish. Ear, nose, and throat as well as neck examination within normal limits. The heart and lung sounds were normal. Bowel sound was normal. The abdomen was tender atright upper quadrant, no distention, no sign of generalized peritonitis, no palpable liver, spleen, nor mass. There was no shifting dullness, nor sign of liver cirrhosis. Extremities shown no edema. Skin all over the body looked yellowish including the palm and the sole. Pruritic scar

was noted in some area but no pustule nor bullae documented.

The laboratory investigation result was normal. Complete blood count with hemoglobin (Hb) 12.1 g/dL, hematocrite (Ht) 38.7%, leukocytes 10.200 mm³ and thrombocytes 321.000 mm³. Liver function test showed increase of total bilirubin at 4.49 mg/dL with dominance of direct bilirubin 4.39 mg/dL, serum aspartate transaminase (AST) 158.4 U/L, alanine aminotransferase (ALT) 198.3 U/L, alkaline phosphates (ALP) 483 mg/dL and gamma glutamyltransferase (GGT) 715 U/L. Coagulation profile, shown international normalized ratio (INR) 1.11 with partial thromboplastin time (PPT) was 13.0 with control at 12.4, activated partial thromboplastin time (APTT) was 36.6 with control at 31.9. Renal function test shown BUN 9.0 mg/dL and creatinin serum 0.44 mg/dL. Urinalysis shown brown color, urobilinogen 8 mg/dL (+++), bilirubin 6 mg/dL (+++). Antibody testing of HBsAg (Elisa) and anti HAV IgM result showed no evidence of hepatitis A or B infection. The blood and urine culture shown no bacterial growth. Stool sample shown pale color.

Abdominal ultrasonography revealed a cystic lesion in extrahepatal bile duct. The finding was most compatible with a choledochal cyst (**Figure 1**).

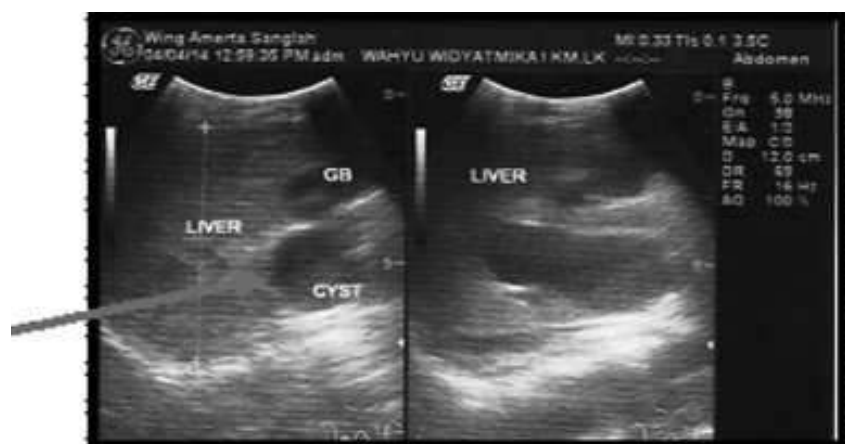


Figure 1. Abdominal ultrasonography showed a cystic lesion in extrahepatal bile duct.

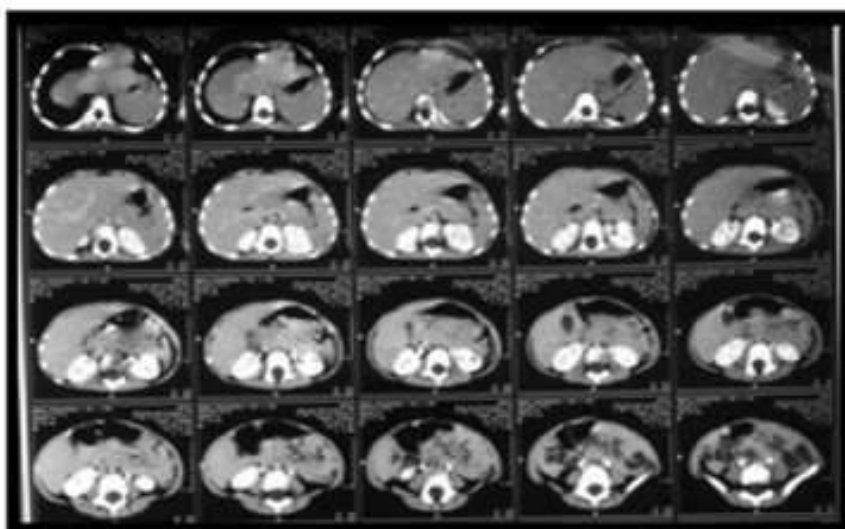


Figure 2. Abdominal computed tomography scan showed type IC choledochal cyst.

Abdominal computed tomography scan (CT scan) revealed a celled in hepatic communis ductal confirmed with the diagnosis of type IC choledochal cyst (**Figure 2**).

Based on clinical manifestation, and imaging findings, we assessed the patient with type IC choledochal cysts. Treatment plan were cyst removal surgery and Roux-en-y hepaticojejunostomy. Before underwent the surgery, patient had none per os, hence

intravenous 5% glucose to 0.25% normal saline fluid was instituted. A 300 mg intravenous ceftriaxone twice daily with 120 mg metronidazole three times daily were given for preoperative injection prophylaxis. A 2 mg K vitamin injection intra-muscular every 3 weeks, 120 mg oral ursodioxycholic acid (UDCA) three times daily, 4 g oral cholestyramine once daily, 10.000 IU oral vitamin A once daily, 300 IU oral vitamin E once daily, 2.5 µg oral vitamin D once

daily were given to over come cholestasis.

Patient underwent digestive surgery, including laparotomy, common bile duct (CBD) exploration, biliary reconstruction, and cyst excision with biopsy (**Figure 3**). After the surgery was performed, the choledochal cyst as a biopsy sample (**Figure 4**) sent to Anatomy Pathologic department for examination. Clinical improvement was recorded with jaundice appearance gradually disappeared, while intensity of abdominal pain decreased and there was no more itchy skin. Laboratory result after six days post-surgery revealed a normalized level of serum transaminase, normalized bilirubin, and no bacteria growth for the blood and the urine culture. No complication was noted post surgical procedure and patient was discharged in a good condition after seventh day. Two weeks later, the patient came for follow up in good condition of physical and laboratory examination. Pathologic examination from biopsy sample confirmed diagnosis of type IC choledochal cyst.

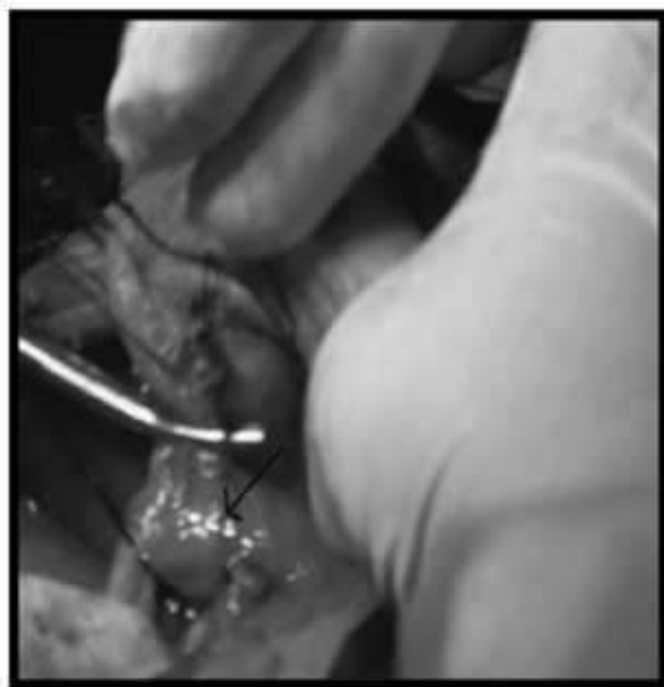

Figure 3. Cyst excision intraoperative.

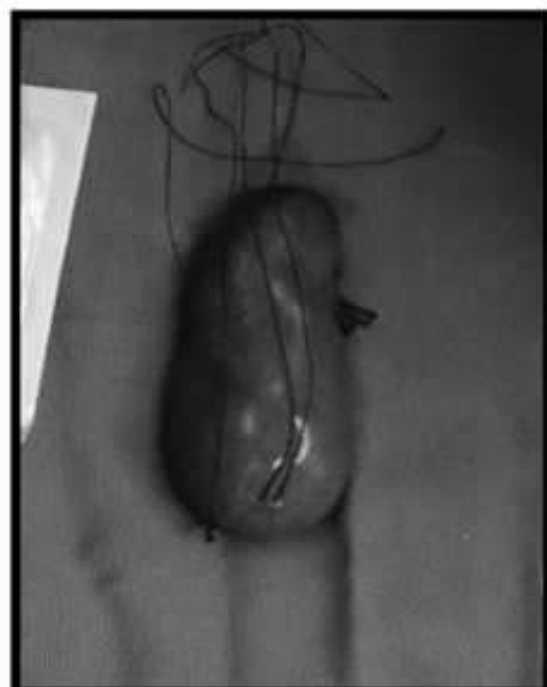


Figure 4. Choledochal cyst.

DISCUSSION

Choledochal cysts are cystic dilation of extrahepatic duct, intrahepatic duct, or both that may result in significant morbidity and mortality, unless it is identified early and managed appropriately.³ Dilated cysts and distal stricture due to chronic inflammation leads to bile stasis, which results in stone formation and infected bile, which in turn results in ascending cholangitis and further obstruction causing abdominal pain, fever, and obstructive jaundice. Chronic inflammation and formation of albumin rich exudates or hypersecretion of mucin from dysplastic epithelium leads to protein plugs in pancreatic duct, which along with distal CBD stone causes pancreatitis. About half of the patients with antenatal diagnosed choledochal cyst are asymptomatic at birth.^{4,5} Since most of the patients have stenosis distal to the cyst, clinical symptoms such as recurrent jaundice, liver dysfunction, ascending cholangitis, pancreatitis and rupture of the cysts are usually seen.⁶

In our case, patient came with symptom and signs of cholestasis. Cholestasis includes retention of conjugated bilirubin, bile salts and other components of the bile. It is a symptom of many diseases, therefore, it is a signal that disease exists. The mechanisms by which diseases produce cholestasis can be classified as either intrahepatal or extrahepatal cholestasis.¹ The first diagnostic concern of cholestasis disorders should be to differentiate either the entity is of intrahepatal or extrahepatal. This is important as the management will be significantly different between medical and surgical.

Early identification of extrahepatal cholestasis that need prompt intervention will improve outcome. However, lack of distinctive clinical features often leading to difficulty in differentiation between intrahepatal and extrahepatal cholestasis.² When diagnostic procedure incorporate clinical, biochemical, radiological and histological features or sometime serologic test or imaging study then probable cause of

cholestasis may be identified.³ In our case, extrahepatal cholestasis was identified based on clinical manifestation and biochemical test, while abdominal ultrasonography and CT scan, identified the cause of the anatomical problem causing extrahepatal cholestasis.

The type of choledochal cysts symptoms depends largely on the age at presentation. Jaundice is reported as the main presenting symptom in infants, while abdominal pain has been reported to be the most frequent symptom at presentation in older child.⁷ It has been suggested that age related difference in presentation is determined by whether there is a reflux of activated pancreatic juice.⁷ It was found that patients with choledochal cysts presenting with abdominal pain were older than one year and that in these patients there is a relation with elevated serum amylase and signs of chronic inflammation in histology sections of the resected cyst.⁸

Previous studies found jaundice as the main presenting symptom of extrahepatic cysts and cholangitis and gall stones of intrahepatic cysts.^{1,8} This may be explained by the localization of the lesion. Extrahepatic cysts may give complete obstruction of the biliary tree leading to jaundice, whereas intrahepatic cysts will lead to partial obstruction giving late and localized complications. The classic triad of abdominal pain, jaundice, and abdominal

mass has proved to be rare.^{8,9} These were confirmed in our case, with initial presentation of jaundice and abdominal pain but with no abdominal mass suggesting a choledochal cyst.

Choledochal cysts belong to the fibropolycystic disorders. Type I cysts are the most frequent choledochal cysts encountered (**Figure 5**). The intrahepatic part of type IVA and type V choledochal cyst located diffusely or in a part in the liver, type IVB, features multiple extrahepatic dilations.^{4,5} Type V (Caroli's disease) and probably the intrahepatic part of type IVA cysts are thought to be ductal plate malformations (DPM).⁴

The precise etiology of extrahepatic cyst is still unclear. Type I cyst are associated with an abnormal arrangement of the pancreatobiliary ducts (APBD), also known as "common channel". A long common channel can be the cause of a variety of pathologic conditions, such as pancreatitis, stenosis of the papilla of Vater, and choledochal cyst.^{2,6} A common channel may enhance reflux of pancreatic juice into bile duct, hence expose the common bile duct wall to pancreatic enzymes, as well as increase pressure in choledochal duct resulting in cyst formation.^{2,6} The complete type of choledochal cysts are as follows:^{1,2} type IA: cystic dilatation of the extrahepatic duct; type IB: focal segmental dilatation of the extrahepatic duct; type IC:

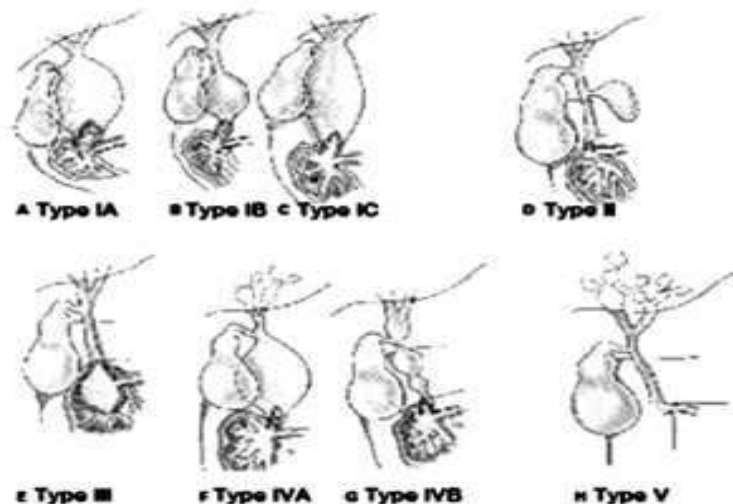


Figure 5. Classification of choledochal cysts according to modified Todani.¹

fusiform dilatation of the entire extrahepatic bile duct and common bile duct; type II: simple diverticulum of the common bile duct; type III: cyst/cholechocele distal intramural dilation of the common bile duct; type IVA: combined intrahepatic and extrahepatic bile duct dilatation; type IVB: multiple extrahepatic bile duct dilations; type V: multiple intrahepatic bile duct dilatation.

In most patients, abdominal ultrasonography is the primary imaging technique for detection of choledochal cysts and usually suffices to establish the diagnosis.⁹ Sensitivity of ultrasonography is about 71–97%.¹³ It is also the preferred investigation in post operation surveillance. After a preliminary ultrasonography, other supportive imaging techniques should be ordered to evaluate biliary system and pancreatic duct. Computed tomography scan is the most accurate for choledochal cyst diagnosis also helps in planning surgical approaches. It is well delineates the intrahepatic biliary dilation in type IVA and Caroli's disease, also the extent of intrahepatic dilation. CT scan also identify cyst wall thickening related to malignancy.¹³ Plain abdominal films, laparoscopy, and gastroduodenoscopy are not used as standard diagnostic tools for choledochal cyst, preoperative biopsies were performed when cancer was suspected, and the lesion was a choledochal cyst.^{1,9,10} In our case the diagnosis of choledochal cyst type IC was established with an abdominal ultrasonography and CT scan.

Treatment of choledochal cyst prior to the onset of symptoms is recommended, as the benefit of reducing risk of cholangiocarcinoma outweighs risk of surgery prior to the development of symptoms.¹¹ Historically, management of choledochal cyst consisted of various drainage operations, but high complication rates and retained threat of malignancy have led to the use of excision or transplantation as first line therapy. The preferred surgical operation is cyst removal and

Roux-en-y hepaticojejunostomy.^{10,11} Our case underwent open surgery and had a right extended subcostal incision without an operative cholangiography. The complete excision of the cyst with a creation of Roux-en-Y hepaticojejunostomy was done as it is the treatment of choice. Long term outcome of patients after underwent complete excision with Roux-en-Y hepaticojejunostomy are alive, with symptoms free survival rate and overall survival rate were 89% and 96%, respectively. If choledochal cysts are not resected, a high incidence (20% to 30%) of cholangiocarcinoma has been reported, mainly after the second decade of life, which formed the basis of resection as state of the art surgical treatment. This policy is further supported by a study that found increasing rate of premalignant changes in resected cysts with advancing age.⁶

SUMMARY

We reported a choledochal cyst in a 3 year old boy who presented with the two out of three classic triad of abdominal pain, palpable abdominal mass, and jaundice. Ultrasonography and CT scan confirmed diagnosis and the type of choledochal cyst. Primary cyst excision with Roux-en-Y bilioenteric drainage showed a good result post surgically with normalized clinical and biochemical profile. Long term follow up still needed to ensure free survival state.

REFERENCES

1. Lu S. Biliary cysts and strictures. In: Kaplowitz N, editor. *Liver and Biliary Diseases*. Chicago: Williams and Wilkins; 1996. p. 739-53.
2. Lipsett P. Biliary atresia and cysts. In: Pitt H, editor. *The Biliary Tract (Part of Clinical Gastro Enterology)*. London: Balliere Kindall; 1997. p. 626-41.
3. Todani T, Watanabe Y, Narusue M, Tabuchi K, Okajima K. Congenital bile duct cysts, classification, operative procedures, and review of thirty-seven cases including cancer arising from choledochal cyst. *Am J Surg*. 1977;134:263-9.

4. Ludwigs DV. Symposium on biliary disorders - part I: Pathogenesis of ductal plate abnormalities. *Mayo Clin Proc*. 1998;73:80-9.
5. David J. Cysts and congenital biliary abnormalities. In: Sherlock S, Dooley J, editors. *Diseases of liver and biliary system*. London: Horizon Inc; 1997. p. 579-91.
6. Komi N, Takehara H, Kunitomo K, Miyoshi Y, Yagi T. Does type of anomalous arrangement of pancreaticobiliary ducts influence the surgery and prognosis of choledochal cyst? *J Pediatr Surg*. 1992;27:728-31.
7. Samuel M, Spitz L. Choledochal cyst: varied clinical presentation and long-term results of surgery. *Eur J Pediatr Surg*. 1995;6:78-81.
8. Stringer M, Dhawan A, Davenport M, Mieli VG, Mowat AP, Howard ER. Choledochal cysts: lessons from 20 year experience. *Arch Dis Child*. 1995;73:528-31.
9. Vries JS, De-Vries S, Aronson DC, Bosman DK, Rauw AJ, Bosma HA, *et al*. Choledochal cysts: age of presentation, symptoms, and late complications related to Todani's classification. *J Pediatr Surg*. 2002;37:1568-73.
10. Akhan O, Demirkazik FB, Ozmen MN, Ariyurek M. Choledochal cysts: ultrasonographic findings and correlation with other imaging modalities. *Abdom Imaging*. 1994;19:243-7.
11. Dhupar R, Gulack B, Geller DA, Marsh JW, Gamblin TC. Research article: the changing presentation of choledochal cyst disease: an incidental diagnosis. *HPB Surgery*. 2009;2009:1-4.
12. Lipsett PA, Pitt HA, Colombani PM, Boitnott JK, Cameron JL. Choledochal cyst disease a changing pattern of presentation. *Ann Surg*. 1994;220:644-52.
13. Bhavsar MS, Vora HB, Giriappa VH. Choledochal cysts: a review of literature. *Saudi J Gastroenterol*. 2012;18:230-6.