

## Management of Spinal Tuberculosis (TB) in Developing Country

**Tjokorda GB Mahadewa**

Neurosurgery Department-Udayana University/Sanglah Hospital- Bali-Indonesia

Correspondence: E-mail: [tjokmahadewa@hotmail.com](mailto:tjokmahadewa@hotmail.com)

**Background:** Tuberculosis on the spine is involved approximately 1 % of all tuberculosis cases. It is a lethal type of TB skeletal due to highly neurologic compromised because of adjacent medullary compression and incidence kyphotic deformity. Early diagnosis and management of this disease is mandatory to prevent serious complications. **Method:** Serial case report was conducted in Sanglah General Hospital from January 2014 until December 2015. All patients were diagnosed based on local protocol using appropriate imaging technique. All patients were treated by anti-tuberculosis drugs for 2 weeks followed by functional assessment by MMT, ASIA, and JOA. **Result:** The author reported 10 patients of spinal TB whom were treated in Sanglah Hospital, Bali between January 2014-Desember 2015. Among pts 8 male and 2 female with location of spinal TB i.e 4 in thoracal, 4 in lumbal and 2 in cervicothoracal. Preoperative ASIA scale was an average scale C and postoperative ASIA scale was in D. The average JOA pre-surgical score was 10.5 and postsurgical was 14.5. Improvement using the formula JOA achieved with an average of 21.6 %. All patients neurologically improved, no complications and surgical implant failures in this series. **Conclusions:** Surgical management of spinal tuberculosis, if delivered with appropriate indication, proved to be effective in correcting spinal kyphosis. Early management is mandatory in order to ensure better prognosis.

**Keywords:** Spinal tuberculosis, management, pitfalls.

**DOI:** 10.15562/bmj.v5i2.245

**Cite This Article:** Mahadewa, T. 2016. Management of Spinal Tuberculosis (TB) in Developing Country. Bali Medical Journal 5(2). DOI:10.15562/bmj.v5i2.245

### INTRODUCTION

Tuberculosis is a disease that mostly affects low economic class or area. HIV co-infection rise the risk contacting tuberculosis even more, around 20-37 times greater compared to those without HIV. There were 1.2 million new tuberculosis cases with HIV reported in 2009 in which 90% located in Africa and South East Asia.<sup>1,2</sup>

Spinal tuberculosis is one form of extra pulmonary tuberculosis that is frequently encountered. This form is rare in developed country, mainly encountered in immigrants from endemic area.<sup>3</sup> Currently, there is no reliable data about incidence and prevalence of spinal tuberculosis either globally or per nation. However, in area with high burden of tuberculosis, the incidence could be proportionately high since it is estimated that 10% of pulmonary tuberculosis will have skeletal involvement.

### Corresponding author:

**Tjokorda GB Mahadewa**

**Address:** Neurosurgery Department-Udayana University/Sanglah Hospital- Bali-Indonesia

**Email:** [tjokmahadewa@hotmail.com](mailto:tjokmahadewa@hotmail.com)

The spine is the most common skeletal site affected, followed by the hip and knee. Spinal

tuberculosis accounts for almost 50% cases of skeletal tuberculosis.<sup>4</sup>

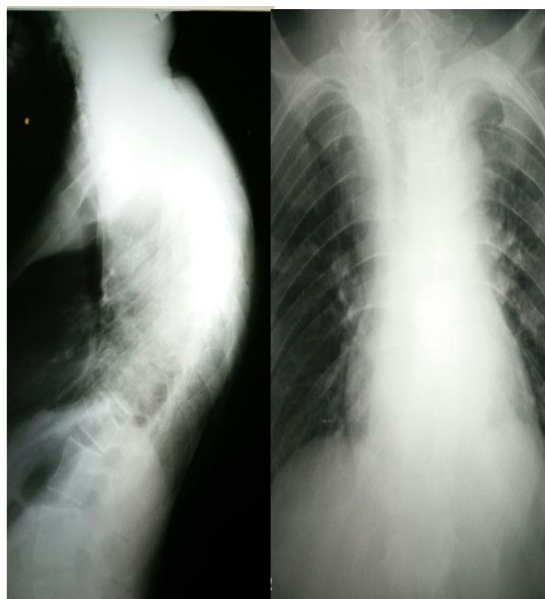Human immunodeficiency virus (HIV) pandemic caused tuberculosis resurgences globally which made increased awareness about spinal tuberculosis become crucial. Despite its predictably high occurrence and morbidity, there are no comprehensive guidelines for diagnosis or management of spinal tuberculosis. However, it is generally agreed that early diagnosis and prompt management is crucial in order to prevent permanent deformity and neurological disability.<sup>3</sup>

### MATERIAL AND METHODS

Serial case report was conducted in Sanglah General Hospital from January 2014 until December 2015 to describe the method used in spinal tuberculosis management. The diagnosis was confirmed based on local protocol which included imaging study such as plain spine x-ray (Fig. 2 and 3), CT (computed tomography) scan and MR (magnetic resonance) imaging. All patients were treated using anti TB minimum for 2 weeks and indicated for surgery due to cord compression. This series excluded non neurological deficit spinal TB which is treated by anti TB only.

Manual muscle test (MMT) was used to evaluate patients muscle strength. All patients

underwent posterior approach and all patients used body brace for minimum 2 months and continued physical therapy for two months. Plain x - ray obtained at day 3 post- surgery and after 2 months of follow up. Follow up CT scan obtained at 8 weeks postoperatively and at least 2 months of follow-up was performed in all patients (range 2-24 months). Neurologic status were recorded after 2 months of follow up. American Spinal Injury Association (ASIA) scale was used to measure the neurological condition. The JOA (Japanese Orthopaedic Association) scoring system for evaluation of myelopathy. All of the aforementioned procedure was conducted by the author.

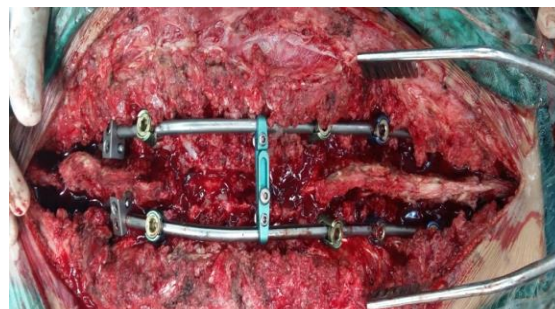


**Figure 1.**

Plain spinal x-ray of thoracic spine show significant bone abnormality as kyphotic deformity.

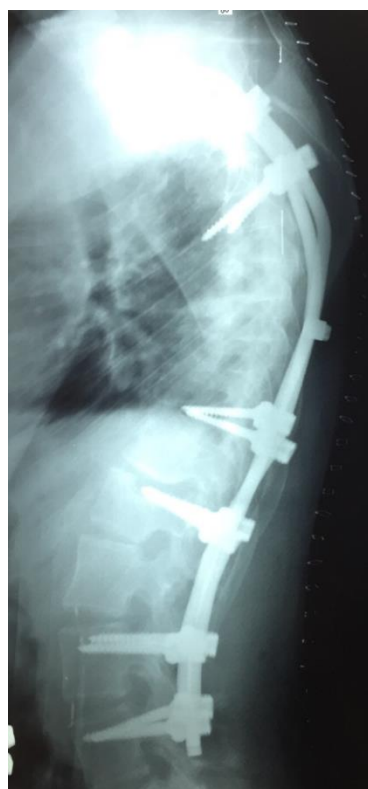
## RESULTS

There were ten patients (8 men and 2 women) of spinal TB diagnosed by imaging study (**Figure 1**). Patients underwent single stage posterior approach of laminectomy decompression stabilization fusion (**Figure 2 and 3**) by single author between Jan 2014 and Dec 2015. Mean age 42, range 16 to 64 y.o. All patients had paraparesis range from scale 2/5 to 4/5 in scale of 5 in MMT. Based on ASIA scale preoperatively, it is ranged from B to D as follows: 2 patients (pts) to ASIA B, 4 pts with ASIA C and 4 pts to ASIA D. Functional checked using JOA score revealed preoperative range of 4 to 10. Average presurgical JOA score was 10.5 and postsurgical score was 14.5. Improvement after surgery using the formula improvements achieved by an average of 21.6 % . In the short term surgical results improved in all patients , no infection , no leakage of cerebrospinal fluid , and no implant failure was observed .



**Figure 2.**

Intraoperative view of cervicothoracolumbal spinal decompression and stabilization.



**Figure 3.**

Postoperative x-ray showing instrumentation and correction of kyphotic deformity.

## DISCUSSION

TB is a disease of the spinal vertebrae and drugs anti-tuberculosis has a major efficacy in the recovery process. Handling more conservative approach were reported in several researches for spinal tuberculosis especially without neurological deficit, no stability problems, and deformity but without paravertebral abscess. Anti-TB drug therapy at appropriate starting dose can prevent serious complications (shown on **table 1**)<sup>4,9-10</sup>

Multilevel spinal TB involve two or more vertebrae, or may involve different spine area. Continuous spine lesions are usually seen in immunodeficiency patients. Currently, TB-MDR (tuberculosis multi-drug resistant) is a world problem and is found in 3 % of new cases and 12 % of re-treatment cases. Thus, problems arise not only

because of low body immunity associated with HIV disease but also the emergence of organisms resistant to anti-TB drugs.

Low patient compliance in taking the drug appropriately also affects the development of resistant germs. Indication for operation at Pott's disease includes neurological deficits, abscess paravertebral, spinal instability, anti TB resistance, and to prevent the complications of paraplegia in the future.<sup>9</sup> Various techniques are used to manage spinal deformity due to TB. Smith-Peterson

osteotomy (SPO) or pedicle subtraction osteotomy (PSO) alone may not adequate to realign the deformity if Konstam angle more than 90°. Combined resection spine through an anterior-posterior approach one stage associated with high morbidity due to significant blood lost. In the other hand, conventional two-stage technique provide decompression with better long-term result, but two operations are needed and may increase the length of stay and patient morbidity.<sup>9-10</sup>

**Table 1.** Regimen anti TB base on disease category<sup>11</sup>

Disease category	Tuberculosis patient definition	Treatment regimen	
		Initial phase (daily or three times weekly)	Continuation phase (daily or three times weekly)
I	New smear-positive New smear-negative with extensive parenchymal involvement New severe extra-pulmonary tuberculosis or severe concomitant HIV infection	2 HRZE	4 HR or 6 HE daily
II	Previously treated sputum Smear-positive pulmonary tuberculosis - Relapse - Treatment after interruption - Treatment failure	2 HRZES/1 HRZE	5 HRE
III	New smear-negative pulmonary tuberculosis Extra-pulmonary tuberculosis	2 HRZE	4 HR or 6 HE daily
IV	Chronic and MDR tuberculosis	Specially designed standardized or individualized regimens	

Multilevel vertebral body resection modified through posterior approach only has been introduced by Wang et al for the management of kyphotic deformity. They reported good results through multilevel resection of posterior vertebral column of severe Pott's with Konstam angle of more than 90°. Based on the above, author conducted a small study to show that a single posterior approach and careful operation with multilevel osteotomies can deliver similar results but a lower risk for the safety and comfort of patients (Figure 5). The basic idea is similar to the technique of reverse stretching the bow inside out, the wider the range of the bow is lighter power needed to reverse the arc angle.

## CONCLUSION

Surgical indications of spinal tuberculosis were indicated based on several conditions such as the presence of neurological deficits, instability especially spinal deformity, abscesses or if the patient is proven resistant to anti-TB drugs. SPO multilevel techniques with spinal instrumentation installation that is not only centered on the thoracic level but also involving the cervical to the lumbar segments is an effective method to manage

kyphosis deformity. Early management of spinal TB cases in young patients and its spinal deformity by surgery and prompt anti-tuberculosis drugs combination is mandatory to maintain good prognosis and recovery.

## REFERENCES

- World Health Organization. HIV/TB Facts 2011. [http://www.who.int/hiv/topics/tb/hiv\\_tb\\_factsheet\\_june\\_2011.pdf](http://www.who.int/hiv/topics/tb/hiv_tb_factsheet_june_2011.pdf)
- World Health Organization. 2010/2011 tuberculosis global facts. Facts sheet no 104, 2010 Nov. Available at: <http://www.who.int/mediacentre/factsheets/fs14/en>.
- Jain AK. Tuberculosis of the spine: a fresh look at an old disease. J Bone Joint Surg Br 2010;92(7):905-13
- Gautam MP, Karki P, Rijal S, Singh R. Potts spine and Pott's paraplegia. J Nep Med Assoc 2005;44(159):106-15.

5. Moorthy S, Prabhu NK. Spectrum of MR imaging findings in spinal tuberculosis. *AJR Am J Roentgenol.* 2002; 179 : 979–83
6. Pertuiset E, Beaudreuil J, Liote F, et al. Spinal tuberculosis in adults, A study of 103 cases in a developed country, 1980-1994. *Medicine (Baltimore)* 1999 ;78 : 309–20.
7. Hidalgo JA, Alangaden G, Cunha BA, et al. Pott disease: tuberculous spondylitis-New York: WebMD LLC; 2008. [cited 2016, May 15]. Available from: <http://emedicine.medscape.com/article/226141-overview>.
8. Nussbaum ES, Rockswold GL, Bergman TA, Erickson DL, Seljeskog EL. Spinal tuberculosis: a diagnostic and management challenge. *J Neurosurg.* 1995; 83 :243–7.
9. Jain AK. Tuberculosis of the spine: a fresh look at an old disease. *J Bone Joint Surg Br.* 2010; 92 : 905–13.
10. Brisson-Noel A, Aznar C, Chureau C, et al. Diagnosis of tuberculosis by DNA amplification in clinical practice evaluation. *Lancet.* 1991;338:364–366.
11. [Mohammad RR](#), [Maryam M](#), [Alexander RV](#), [Kourosh KY](#), [Vafa RM](#). Spinal tuberculosis diagnosis and management. *Asian Spine J.* 2012 Dec; 6(4) : 294–308.



This work is licensed under  
a Creative Commons Attribution