

CASE REPORT

Primary Pulmonary Lymphoma with Superior Vena Cava Syndrome

Alfian Nur Rosyid^{1*}, Resti Yudhawati Meliana¹

¹Department of Pulmonology, Faculty of Medicine, Universitas Airlangga, Surabaya, Indonesia

ARTICLE INFO

Article history:

Received 28 September 2018

Received in revised form 2

October 2018

Accepted 9 October 2018

Keywords:

Primary Pulmonary Lymphoma,
CHOP Regimen.

ABSTRACT

Primary Pulmonary Lymphoma (PPL) is a clonal proliferation of lymphoid cells that involve one or two lungs (parenchyma and or bronchi. PPL is found in approximately 0.4% of all lymphoma cases and 3.6% of NHL cases. Five years survival rate at stage I and II is 90%, and 80% in stage III and IV. A 63-year-old male farmer presented with chief complaint of shortness of breath for one week before admission and preceded by coughing for a month, loss of appetite and night sweating. There was an abnormal physical examination on the right side of the chest with non-tender lymph node enlargements in the right supraclavicular and neck region and superior vena cava syndrome. CT guided FNAB suggesting NHL. Patient was treated with CHOP chemotherapy regimen. However, with high grade lymphoma, patient did not respond well.

© 2018 Biomolecular and Health Science Journal. All rights reserved

Introduction

Pulmonary tumors are all malignancy in the lungs, including Small Cell Carcinoma and Non-Small Cell Carcinoma.¹ While non-lymphoma mediastinal malignancies are thymoma, Seminoma, and Teratoma.² The presence of lymph nodes in the (lung) parenchyma containing lymphocytes that can transform to be malignancy.^{3, 4} Lymphoid tissue contains B and T lymphocytes. Both are part of the immune system which is important to eradicate infections. However, excessive lymphocyte activation, proliferation and differentiation can induce lymphoma.^{5, 6}

The basic diagnosis is elevated LDH tumor markers with histopathological finding of malignant lymphoma.⁷ Lymphomas are divided into two, Hodgkin Lymphoma (HL) and Non-Hodgkin lymphoma (NHL), which is about 90% of all cases. Lymphoma in the thoracic region can be from the mediastinum or lung, which is less frequent (0.4% of all cases).^{5, 8}

The presence of a mass in the center of the lung with pathological finding suggesting NHL, with thoracic CT-Scan suggesting pulmonary primary origin is a rare case (3.6% of NHL cases and known as PPL (Primary

Pulmonary Lymphoma)).⁹ This report discusses a rare case of PPL in an immunocompetent patient with vena cava superior syndrome.

Case Report

A 63-year-old male patient, worked as a farmer, from Madura, was hospitalized in the pulmonary disease inpatient ward of Dr. Soetomo General Hospital Surabaya with the chief complaint of shortness of breath for one week before admission. It was preceded by coughing for a month. His appetite was decreased accompanied by weight loss without night sweating. There was no history of Diabetes Mellitus, hypertension, asthma, Tuberculosis treatment, tattoo, and free sex.

There were non-tender lymph node enlargements in the right supraclavicular and neck region. Jugular venous pressure was increased with face swelling. There was an asymmetrical chest movement, with the right hemithorax tardiness, and dilated collateral vein. The vocal fremitus of the right hemithorax was decreased. The two-third of the right upper lung had reduced breath sounds. His right arm and shoulder were edema with collateral vein dilation in both arms.

* Correspondence: alfian-n-r-10@fk.unair.ac.id

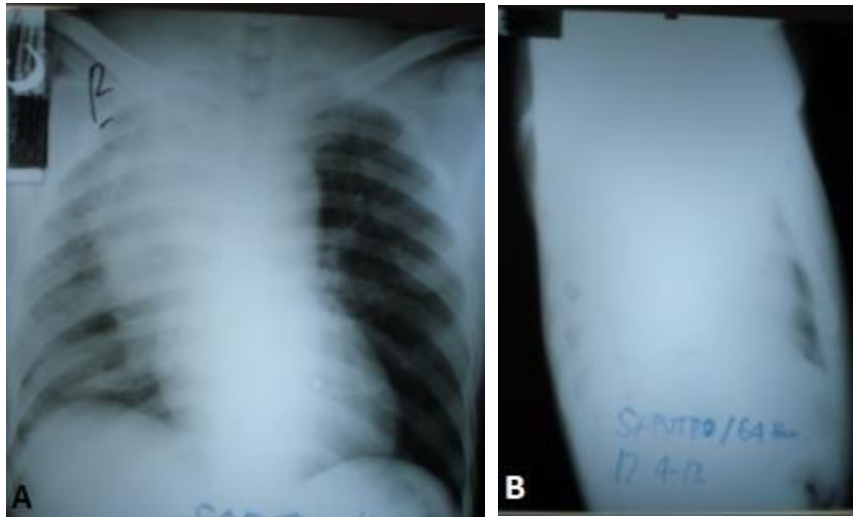


Figure 1. Chest X-Ray A. posteroanterior and B. lateral right position. A homogeneous opacity on the apex and the right para hiller with irregular borders, suggesting a right lung mass.

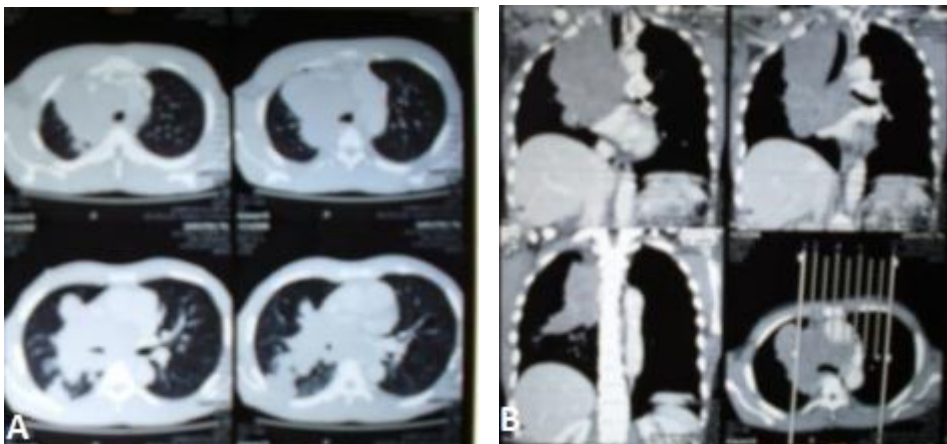


Figure 2. Thoracic CT Scan with contrast: A. Horizontal plane and B. Coronal plane showed a mass at the center of the right lung sized 9.4 x 8.2 x 12 cm penetrating the mediastinum and attached to the posterior thoracic wall. The mass obstructs the superior branch of the right bronchus accompanied by atelectasis, and encase the superior vena cava and right pulmonary artery accompanied by thrombus.

Laboratory examination were all within normal limits, except there was mild hypoxia and blood sedimentation rate increased. Sputum cytology found no malignancy. Blood films suggesting the absence of bone marrow involvement. The Thoracic CT Scan showed sub-carina lymph nodes enlargement ($T_4N_2M_x$) (Figure 2).

Then a CT guided FNAB was done, suggesting NHL. Abdominal Ultrasonography found nodules in para-aorta. Tumor markers are within normal limits, however LDH was elevated, suggesting a lymphoma. From spirometry, we found a mild restriction without obstruction. From FOB, we found intraluminal mass covering the opening of superior lobe causing total obstruction, smooth mucosa and hypersecretion. From

Immunohistochemistry, we found pan-cytokeratin antibody staining was negative; positive CD45; negative CD20, suggesting T-cell type of NHL. It was concluded that the patient had NHL with pulmonary primary origin at stage III B.

Based on the diagnosis, patient was treated with CHOP chemotherapy. The patient's BSA was 1.58, so the chemotherapy doses were Cyclophosphamide 1,185 mg, Adriamycin 79 mg, Vincristine was 2 mg. All the drugs above were given on the first day accompanied by Prednisone 3x20 mg until the fifth day. CHOP chemotherapy was planned 6 cycles with 21 days intervals. Patient did not come for cycle II and died a month afterward.

Discussion

Primary Pulmonary Lymphoma (PPL) is a clonal proliferation of lymphoid cells that involve one or two lungs (parenchyma and or bronchi) where extrapulmonary involvements are not found when diagnosis determined or for three months afterward. PPL is found in approximately 0.4% of all lymphoma cases and 3.6% of NHL cases.^{2,3}

The ratio of male and female with PPL varies from 1:1 to 2:1. The average age of patients is 53 ± 12 years. Approximately 83% of patients are over 40 years old.³ patients with low grade are usually at sixth and seventh decades of life.¹⁰

The etiology of malignant lymphoma is still unclear, probably due to genetic mutations, caused by viruses, chemicals, spontaneous mutations, radiation, etc.⁴ This patient was a farmer who often exposed to chemicals. The risk factors of lymphoma are older age, gender, race, ethnicity and geography, chemical exposures, history of chemotherapy, radiation, immune system deficiency, autoimmune diseases, obesity and diet.^{5,11}

Symptoms appears based on the location of the lymph nodes enlargement. Cough and shortness of breath can be found in patients with lungs involvement. Other organ involvements can be abdominal, respiratory tracts, central nervous system, and bone marrow.⁸ Patients with slow-growing lymphoma have painless lymph nodes enlargement. While patients with moderate and severe lymphoma can show symptoms of fever, night sweating and weight loss.⁹

Elevated LDH tumor marker can be used to diagnose lymphoma. However, complete blood counts, liver and

kidney function test, protein electrophoresis, urinalysis, and electrolytes need to be performed although those tests are not specific.⁷ In this patient, the LDH elevated by 1175 U/L, suggesting lymphoma.

PPL is divided into two based on immunohistochemistry test, namely B cells and T cells.¹¹ These lymphomas then grouped into 4 based on the characteristics of the tumor: Small B cells, medium B cells, large B cells, and T cell.³ Keratin staining was negative in lymphoma.¹² Positive CD3, CD 45 and negative CD20, CD30, CD56 suggesting T cell lymphoma.¹³ In this patient, the Pan-cytokeratin staining was negative, positive CD45 and negative CD20 suggesting a rare T cell lymphoma and poor prognosis.

Radiological finding shows uniform non-specific opacity or consolidation that resembles mass in most patients (60-72% of cases). Multiple nodules are seen in more than 50% of cases. Bilateral abnormalities are found in 21-44% of cases. The presence of pleural effusion is found in 15-22% of cases.³ In this patient, there were homogeneous opacity, a mass in the center of the right lung penetrating the mediastinum and attached to the posterior thoracic wall with sub-carina lymph nodes enlargement.

Staging in lymphoma is classified based on clinical and pathological stages. Clinical stages are divided into two subclassifications namely A, if no symptoms found, and B, if systemic symptoms and signs are present. Whereas the pathological staging can be determined by bone marrow biopsy and aspiration, laparoscopy, and pleural fluid cytology.⁷

Histopathological staging based on Modified Ann Arbor criteria for Pulmonary Lymphoma can be seen in table 1.

Table 1. Modified Ann Arbor Staging Systems³

Stages	Description
IE	Only lungs involved, can be bilateral
II 1E	Lungs and hilum lymphoid nodes
II 2E	Lungs and mediastinal lymph nodes
II 2EW	Lungs and chest wall or diaphragm
III	Lungs and lymph nodes under the diaphragm
IV	diffuse metastases in one or more extra nodal organs or tissues with or without lymph nodes involvement
Modifying features	
Stages	Description
A	without symptoms
B	fever $> 38^{\circ}\text{C}$, night sweating, weight loss $>10\%$ in 6 months
X	Bulky disease (mediastinal lymph nodes enlargement $<1/3$, maximum diameter of the mass is 10 cm)
E	One extra nodal organ involvement that is related or proximal to the regional lymph nodes
CS	Clinical stage
PS	Pathologic stage

From the table 1, we can conclude that this patient had stage IIIB PPL. Complication of PPL can be metastases, Superior Vena Cava Syndrome (SVCS), and atelectasis. The most common extra nodal metastases of NHL are hepatic, pleural, pulmonary, and bone marrow.¹⁰ Metastases are common in low grade B cells lymphoma. SVCS appears as the result of superior vena cava blockage, the symptoms are face and right arm swelling, increased JVP, and dilated collateral vein on the right chest.⁷ While atelectasis appears due to bronchial obstruction.¹¹ In this patient, a mass obstructed the superior branch of right bronchus causing atelectasis and encased the superior vena cava accompanied by thrombus causing SVCS.

The treatments of lymphoma are radiotherapy, surgery, chemotherapy, immunotherapy, and transplantation. Radiotherapy and immunotherapy with CD20 anti-antibody are suitable for the patients with slow-growing lymphoma. Surgery is indicated in 60-70% cases, but this patient was non-operable because of the size and the location of the mass. Chemotherapy is given to patients with intermediate grade subclassification B of NHL.⁹ Chemotherapy regimens are Cyclophosphamide, Adriamycin, Vincristine, dan Prednisone.⁷ The dose given is individual based on BSA. Side effects of CHOP chemotherapy are dry mouth, nausea, and vomiting. Moreover, CHOP regimen is potentially toxic to the heart, nerve, lung, and liver¹⁴ in which monitored through laboratory blood test and echocardiography.¹⁵ Patients also susceptible to secondary infections, hair loss, fatigue, and constipation. This patient was treated with CHOP Chemotherapy, 6-8 cycles with 21 days intervals.

The International Prognosis Index (IPI) mentions several prognostic factors for non-Hodgkin's lymphoma can be seen in table 2.

Table 2. The International Prognostic Index (IPI)

Characteristics	Risk factors (1 point each)
Age	>60 years
Karnofsky	<80%
Stadium	>II
LDH	Upper normal limit
Lymph nodes enlargement	>1 extra nodal

Score : 0-1 low risk, 2 low-intermediate risk, 3 high-intermediate risk, 4-5 high risk.¹¹

From the table, we can conclude that the prognosis of this patient was poor considering that the age above 60 years, stage IIIB, high LDH levels, and more than one extra nodal lymph nodes enlargement. The score in this patient was 4 with Karnofsky > 80%.

Median survival rate of patients with slow-growing lymphoma is around 6-8 years.⁴ Five years survival rate at stage I and II is 90%, while in stage III and IV is 80%.⁸ This patient has a poor prognosis with low survival. Patient died one month after diagnosis and chemotherapy cycle I were done..

Conclusion

The patient was diagnosed with PPL and SVCS treated with CHOP Chemotherapy. Chemotherapy was planned for 6-8 cycles with 21 days intervals. Patients died 1 month after the first chemotherapy. Poor prognosis made a low survival rate.

Conflict of Interest

The author stated there is no conflict of interest

References

- Murray John F NJA. *Murray & Nadel's Textbook of Respiratory Medicine*. New York: Saunders Elsevier, 2010.
- Kara M, Özkan M, Sak S, Kuzu I and Kavukçu S. Primary Pulmonary Non-Hodgkin Lymphoma. *Journal of Ankara Medical School*. 2002; 24: 201-6.
- Parissis H. Forty Years Literature Review of Primary Pulmonary Lymphoma. *Journal of Cardiothoracic Surgery* 2011; 6.
- Surabaya RDS. *Pedoman Diagnosis dan Terapi Bag/SMF Ilmu Penyakit Dalam*. Surabaya: RSUD Dr. Soetomo, 2008.
- Vinjamaram S and Besa E. Non-Hodgkin Lymphoma.
- Smedby K. Epidemiology and Etiology of Non-Hodgkin Lymphoma - a Review. *Acta Oncologica*. 2006; 45: 258-71.
- Tjokroprawiro A, Setiawan P, Santoso D and Soegiarto G. *Buku Ajar Ilmu Penyakit Dalam*. Surabaya: Airlangga University Press, 2007.
- Ko A, Rosenbaum E and Dollinger M. *Everyone's Guide to Cancer Therapy: How Cancer is Diagnosed, Treated, and Managed Day to Day*. Kansas city: Andres McMeel Publishing LLC, 2008.
- McPhee S and Papadakis M. *Current Medical Diagnosis & Treatment*. New York: McGrawHill Lange, 2010.
- Li G, Hansmann M, Zwingers T and Lennert K. Primary Lymphomas of the Lung: Morphological, Immunohistochemical and Clinical Features. *PubMed*. 1990; 16: 519-31.
- Supandiman I, Sumantri R, Heri F, Irani F and Oehadian A. *Pedoman Diagnosis dan Terapi Hematologi Onkologi Medik*. Bandung: Q-Communication, 1997.
- Dabbs D. *Diagnostic Immunohistochemistry: Theranostic and Genomic Applications*. Philadelphia: Saunders, 2010.
- Shin C, Paik S, Park J, et al. Primary Pulmonary T-Cell Lymphoma: a Case Report. *Korean J Radiol*. 2010; 11: 234-8.
- PDPI. *Tumor Mediastinum (Tumor Mediastinum Non Limfoma): Pedoman Diagnosis & Penatalaksanaan di Indonesia*. Jakarta: PDPI, 2003.
- PDPI. *Kanker Paru Jenis Karsinoma Bukan Sel Kecil: Pedoman Nasional untuk Diagnosis & Penatalaksanaan di Indonesia* Jakarta: PDPI, 2005.