

CASE REPORT:**Problem diagnostic of Krukenberg tumor**

**Reza Wangsanagara¹, Pungky Mulawardhana^{1*}, Vicky Sumarki²,
Anny Setijo Rahaju³, Tri Wulanhandarini⁴**

¹Department of Obstetrics and Gynecology, ²Department of Digestive Surgery,

³Department of Anatomic Pathology, ⁴Department of Radiology

Faculty of Medicine, Airlangga University, Dr. Soetomo Hospital, Surabaya, Indonesia

ABSTRACT

Objectives: to report the case of Krukenberg tumor in 57 years old woman, with complaints of abdominal enlargement since the last 10 months.

Case Report: a 57 years old woman, multipara, post menopause, came to our hospital with complaints of enlarging abdomen. Abdominal physical examination showed enlarging abdomen, hard palpable mass, measured 17 cm in diameter, and limited mobility. Abdominal CT result showed solid mass of the right adnexal, expanding to upper right abdomen, omental cake, ascites, and left pleural effusion, right lobe hepatic cyst and multiple bilateral renal cysts. Patient was diagnosed as solid ovarian tumor, suspicious of malignancy. Colonoscopy revealed hemorrhoid interna. Total abdominal hysterectomy with bilateral salpingo-oophorectomy was done. Histopathologic findings showed malignant ovarian tumor, signet ring cell carcinoma of the cervix, endometrium, myometrium, nodule in gastrocolica ligament, and prevesica urinaria nodule. IHC examination of the ovarian tumor showed possible source was of colorectal, supporting the diagnosis of Krukenberg tumor with CK20 (+) and CK7 (-)

Conclusion: Krukenberg tumor is a rare ovarian malignancy. Clinical symptoms usually consist of abdominal distension, pain caused by large ovarian mass. Diagnosis of Krukenberg tumor is confirmed by characteristic histologic findings of malignant signet ring cells with cellular stroma. Management for ovarian tumor is surgery removal, with very poor prognosis.

Keywords: Ovarian tumor; Krukenberg; signet ring cell carcinoma

ABSTRAK

Tujuan: melaporkan kasus tumor Krukenberg pada wanita 57 tahun, dengan keluhan perut membesar yang dialami sejak 10 bulan terakhir.

Laporan Kasus: Perempuan usia 57 tahun, multipara, sudah menopause datang ke poli rawat jalan dengan keluhan perut membesar. Pemeriksaan fisik abdomen tampak perut membesar, teraba massa padat dengan ukuran 17 cm, mobilitas terbatas. CT scan abdomen menunjukkan massa solid adneksa dekstra, meluas hingga abdomen kanan atas, disertai omental cake, ascites, dan efusi pleura sinistra, kista hepar lobus dextra dan kista ginjal multipel bilateral. Pasien didiagnosis sebagai tumor padat ovarium curiga keganasan. Kolonoskopi ditemukan hemorrhoid interna. Dilakukan tindakan total abdominal hysterectomy dengan bilateral salpingo-oophorectomy. Pemeriksaan histopatologi menunjukkan tumor ganas ovarium, signet ring cell carcinoma pada serviks, endometrium, miometrium, nodul ligament gastrocolica dan nodul prevesica. Hasil pemeriksaan IHC dari tumor ovarium menunjukkan kemungkinan berasal dari kolorektal, yang mendukung kearah diagnosis tumor Krukenberg dengan hasil CK20 (+) dan CK7 (-).

Simpulan: Tumor Krukenberg merupakan kasus keganasan ovarium yang jarang ditemukan. Gejala klinis umumnya berupa distensi abdomen dan nyeri yang disebabkan oleh massa ovarium. Diagnosis tumor Krukenberg ditegakkan berdasarkan gambaran histologis yang khas berupa malignant signet ring cells, dengan stroma seluler. Penanganan utama berupa pembedahan, dengan prognosis sangat buruk.

Kata kunci: Tumor ovarium; Krukenberg; signet ring cell carcinoma

***Correspondence:** Pungky Mulawardhana, Department of Obstetrics and Gynecology, Faculty of Medicine, Universitas Airlangga, Dr Soetomo Hospital, Jalan Prof dr Moestopo 6-8, Surabaya 60286, Indonesia. E-mail: pungkym@yahoo.co.uk

pISSN:0854-0381 • eISSN: 2598-1013 • doi: <http://dx.doi.org/10.20473/mog.V27I12019.34-39>

• Maj Obs Gin. 2019;1:34-39 • Received 15 Feb 2018 • Accepted 11 Jul 2018

• Open access under CC-BY-NC-SA license • Available at <https://e-journal.unair.ac.id/MOG/>

INTRODUCTION

Ovarian cancer accounts for 2.4-5.6% of all malignancy among woman, after cervix cancer and endometrium cancer. Risk of death caused by ovarian cancer before age 75 years old is higher in developing countries compared to developed countries. The incidence varied around the world, where it is twice higher in developed countries compared to developing countries. Incidence of ovarian cancer in West Europe is higher compared to other geographic area, such as North America, Africa and China, that is about 12 women per 100.000.^{1,2} According to data from Surveillance, Epidemiology and End Results (SEER), mean age of patient with ovarian cancer is 63 years old. Five to ten percent of ovarian tumor is metastatic from other organ, most commonly is from endometrium, appendix (adenocarcinoid atau mucinous adenocarcinoma), breast, colon, pancreas and gaster. About 70 – 80% of ovarian tumor was found when already metastasized. Five year survival rate for the first stage is about 92%, decreasing as the increase of ovarian tumor's stage.³ In Indonesia, ovarian cancer is the third most common disease after breast cancer and cervical cancer. Ovarian cancer often arises in women of late reproductive age, most of them (46.3%) was diagnosed in III stadium.⁴

Krukenberg tumor is a malignant ovarian tumor caused by metastasis most commonly from gastrointestinal tract, but can also be from other tissue such as breast. Abdomen is the most common primary site, but other organs could be the primary source of this tumor. Gastric adenocarcinoma, particularly pylorus, is the main source of Krukenberg tumor. Krukenberg tumor is one of the rarely found solid ovarian tumor. It is estimated to be 30-40% of tumor metastasizing to ovarium, with spreading to transcoelomic sites, and accounts for 1-2% of all ovarian tumor.⁵ Diagnosis of Krukenberg tumor requires histopathologic examination to exclude the possibility of primary ovarian tumor. Based on the data from Oncology-Gynecology Outpatient department of Dr. Soetomo Hospital between 2014 – 2016, only one case of Krukenberg tumor identified from all ovarian cancer. In this case report, we report a case of Krukenberg tumor, referred from Sidoarjo Hospital that we managed and observed from July 2016 to March 2017.

CASE REPORT

In this case report, a 57 year-old woman, previously in good health, came to the community health center in April 2016, complained of enlarging abdomen since 1 month before she sought health provider, without any other complaints. She was then referred to Sidoarjo

Hospital. The patient came to surgery outpatient department of RSUD Sidoarjo in July 2016. On physical examination, there was a palpable mass in the right upper abdomen. She underwent laboratory test, abdominal ultrasound (results not attached) and chest x-ray with findings of left pleural effusion. Tentative diagnosis at the time was adnexal abdominal tumor.

The patient came to Obstetric-Gynecologic Outpatient Department of Dr. Soetomo Hospital. From anamnesis it was found that the patient complaint of enlarging abdomen since March 2016, there was no complaint of digestive or urogenital system abnormalities. The patient had menopause for 7 years, and was not on medication. The patient denied any family history of malignancies. In physical examination. The patient's general state was normal. There was a mass in upper right abdomen, sized 15 x 15 cm. Gynecologic status of vulva and vagina was normal, smooth surface, except there was a >15 cm mass in the right and left parametrium, solid, limited mobility, painless. The patient was diagnosed with solid ovarian tumor, suspected malignancy. Laboratory findings showed increased CA-125 (152.13 u/ml), and CEA (3612 ng/ml), CA 19-9 (< 3.0 u/ml) that led to the diagnosis to malignant ovarian tumor. Chest x-ray showed left pleural effusion. Further work-up with abdominal MSCT was done with findings of solid right adnexal mass sized 17,3 x 14 x 6,1 cm, extending to right upper abdomen, omental cake, ascites, left pleural effusion, right liver lobe cyst, and multiple small bilateral kidney cysts.

Tumor board was then held. The patient was consulted to Digestive Surgery Department for preparation of total abdominal hysterectomy bilateral salphingoophorectomy (TAH-BSO). Colonoscopy was done by Digestive Surgery Department with result of internal hemorrhoid. No erosion or ulcer was found, the mucosa seemed normal, no specific treatment was indicated from the digestive surgery department. During monitoring in outpatient department, the patient underwent chest x-ray evaluation showing minimal pleural effusion, and complete blood test for surgery preparation with unremarkable result. In December 2016, the patient underwent TAH-BSO, omental biopsy and peritoneal biopsy (optimal surgical staging residue < 1 cm), with findings on exploration: slightly enlarged uterus, ascites of approximately 7 liter serous fluid, and solid left adnexal mass sized 15 cm with adhesion to rectum and posterior aspect of uterus, right adnexal solid mass 30 cm in diameter with adhesion to rectum and posterior aspect of uterus, and nodule in supracolica mesenterum. Histopathologic biopsy (2 cm nodule) was done, miliary nodules in prevesical, pararectal, paracolica and ileum surface with diameter <1 cm, infracolica omentum was

not obtained, continued with histopathologic examination of ovarian tumor, VC showed malignancy. The liver enlarged with smooth surface, other abdominal organ did not show any abnormalities.

Histopathology examination revealed as follows: macroscopic findings left ovarian tissue sized 13 x 11 x 7 cm, right ovarian tissue sized 15 x 14 x 12 cm, smooth outer surface, cauliflower-like, homogen solid mass, pale, multilobulated, diameter of 2-7 cm, on slicing showed homogenous solid, lobulated, with a cystic focal area. Gastrocolica was greyish white, solid springy consistency. Prevesical nodule sized 0.3 x 0.2 x 0.1 cm, white greyish, springy solid. Microscopic findings uterus and cervical tissue samples showed tumor growth consisted of round pleomorphic nuclear proliferation, arranged forming gland structure, hyperchromatic, invasive growth into stroma. Gastrocolica ligament

nodule and prevesical nodul showed fibrous connective tissue with similar tumor growth with the uterus. Histopathologic features showed ovarian malignant tumor, signet ring cell carcinoma (Krukenberg tumor) starting from cervical, endometrium, myometrium, gastrocolica ligament nodule, and prevesical nodule, with the diagnosis of Krukenberg tumor. Parafin coupe result of right and left ovarium showed similar features, tissue sample with malignant tumor growth consisted of anaplastic cells proliferation, pleomorphic, with rough cromatin, forming signet ring cell appearance, mostly consisted of solid, others formed gland appearance, invasively growing between stroma of desmoplastic connective tissue. There was lymphangi invasion. The tumor grew through serosal lining. Conclusion for right and left ovarian sample: Signet ring cell carcinoma (Krukenberg tumor).

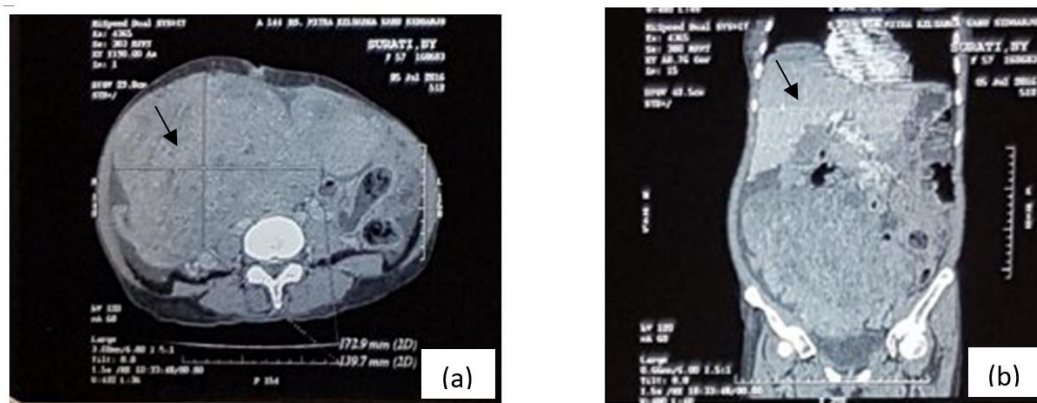


Figure 1. Pre-operative abdominal CT scan. (a) axial slice (b) coronal slice, showing right adnexal solid mass, right lobe liver cyst and multiple renal cysts.

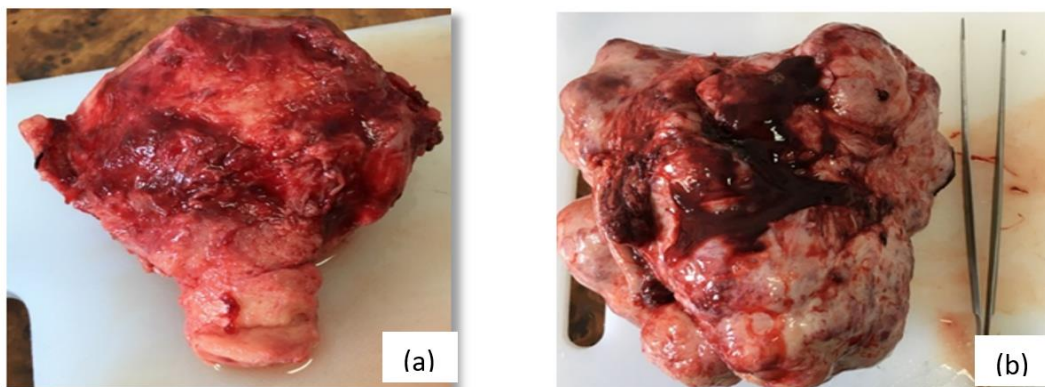


Figure 2. Macroscopic view of the resected tumor specimen (a) uterus and cervical (b) right ovarium, showing smooth outer surface, cauliflower-like, multilobulated.

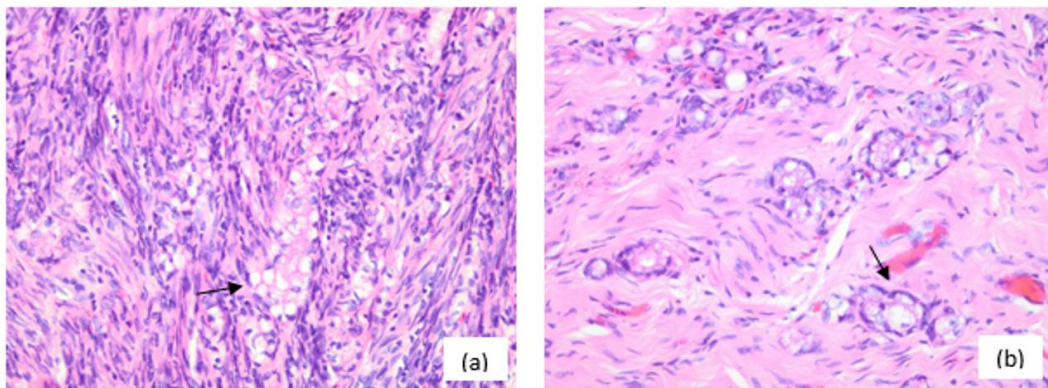


Figure 3. Microscopic images of tissue (a) Endometrium, signet ring cells appearance between ovarian cellular stroma (arrow) (b) gastrocolica, tumor cells arranged in cluster, forming a ring with prominent nucleolus, vacuolisation of cytoplasm, filled with mucin, nucleolus was pushed to the side forming signet ring cell appearance (H&E X400).

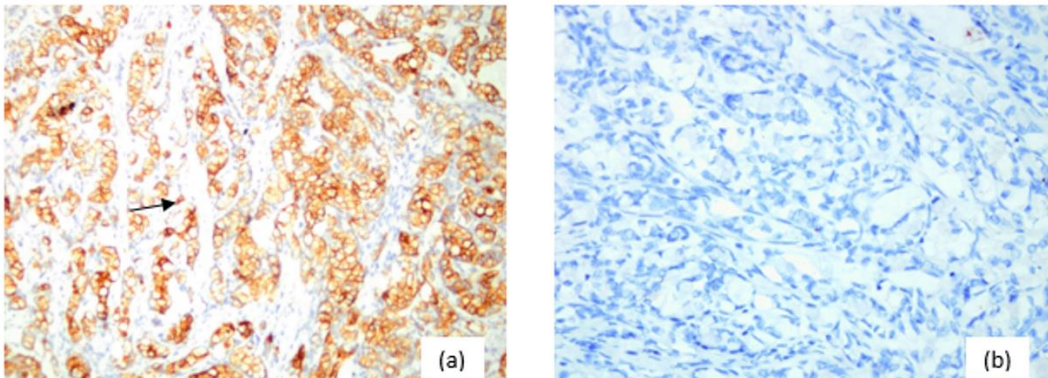


Figure 4. Microscopic view of tissue paraffin (a) positive CK 20 examination shows CK 20 antibody in tumor cell cytoplasm (b) Negative CK 7 examination.

The patient was hospitalized for 1 week. Post surgery, the patient was in well condition. She was sent home in the seventh day post surgery with planned follow-up to surgery and gynecology department. While hospitalized, the patient was stable, no bleeding, no other problems or complaint. While follow-up visits in the outpatient department, chest x-ray evaluation was done with no metastasizing lesion found. Evaluation of CA-125 showed 98.2, decreased compared to the initial result. Immunohistochemistry examination (CK7, CK20) was done, the patient was planned to undergo follow-up to Digestive Surgery Department to locate the primary tumor source. Based on medical record, the patient came to outpatient department in January 2017. In February 2017, the patient underwent abdominal CT scan. At that time, the patient claimed there was no complaint. In February 2017 the patient was reported had passed away. There were no information whether

the cause of death was due to the cancer or due to other complicating disease, because the patient was not brought to the hospital. According to family, the patient complained bloating and loss appetite 1 week before death.

IHC examination showed negative CK 7 in tumor cell and positive CK 20 in cytoplasm of tumor cell, in accordance to tumor originated from gastrointestinal tract. 14 IHC examination of ovarian tumor showed possible colorectal origin, supporting toward diagnosis of Krukenberg tumor with result showed CK 20 (+) and CK 7 (-), in contrary to primary ovarian tumor which should have showed opposite result of CK 7 (+) and CK 20(-). In this patient, the diagnosis was confirmed with increased CEA and supported by IHC examination result that showed positive toward Krukenberg tumor. Although histopathologic findings was in accordance

with metastasis from gastrointestinal tract, no findings supporting presence of gastric cancer was found. The patient also underwent colonoscopy. The patient had internal hemorrhoid, but no mucosal abrasion that indicates malignancy.

Though some examinations was done, no primary source of this tumor was found. However, some findings support metastatic tumor was from gastrointestinal tract. Ovarian tumor in this case had some relevant features, such as component of signet ring cell, nodular bilateral nodular macroscopic features, the tumor grew through serosal linings, and lymphovascular invasion. As mentioned in a study, those characteristics were specific for metastatic ovarian tumor.¹⁶ So the final diagnosis of this patient was Krukenberg tumor, based on the histopathologic examination. After surgery, the patient had several follow-up to outpatient department, she was planned for palliative care and endoscopy for looking the primary site of the metastasis, but unfortunately the patient passed away on February 2017.

DISCUSSION

We reported unusual clinical findings of ascites, pleural effusion, and enlarged abdomen in 57 years old woman, not specific for Krukenberg tumor. Literature showed that about 35-45% was found in the patient aged <40 years (mean age of 40-46 years old). According to Yakushiji, Krukenberg tumor is more often found in pre-menopausal women (40-50 years old).⁶ As for primary ovarian cancer, median age is 65 years old.⁷ This patient was initially not suspected toward metastasizing ovarian tumor from gastrointestinal tract primary malignant tumor. Increase in CA-125 and high CEA should raised awareness of metastatic tumor from gastrointestinal tract. Symptoms usually found are abdominal distention, pain caused by large ovarian mass, and ascites. Ascites is one of the most commonly found symptoms and indicate malignancy.

In this case, the patient complained enlarging abdomen since 10 months before surgery, no gastrointestinal complaints were found. Diagnosis of Krukenberg tumor was confirmed by histopathologic features of malignant signet ring cells, with cellular stroma. Macroscopic specific finding of Krukenberg tumor is multinodular solid mass, and microscopic specific findings is complete infiltration of signet ring cells containing mucin. Some differential diagnosis for Krukenberg tumor are primary ovarian tumor such as Sertoli-Leydig cell tumor, mucinous ovarian carcinoma, clear cell carcinoma, and sclerosing stromal tumor, that can be differentiated based on the microscopic features. It is

very difficult to diagnose Krukenberg tumor using imaging. Both ultrasound and CT-scan have limited specificity in diagnosing, because Krukenberg tumor has no specific imaging features.

Surgery is the only effective measurement in the patient with metastasis limited to ovarium. Management of Krukenberg tumor is primary tumor removal, metastectomy, and adjuvant chemotherapy according to primary tumor. Cheong et al study the role of metastectomy in management of metachronous tumor after curative operation.¹³ The study found mean survival rate for the patient underwent metastatic resection increased significantly compared to non-resected control group.

At present, cytoreductive surgery and Hyperthermic Intraperitoneal Chemotherapy (HIPEC) is the potential therapy for intra-abdominal metastasis originated from colorectal area. Management for Krukenberg tumor itself is still controversial to this moment. In patient with gastrointestinal malignancy, prophylactic oophorectomy while cytoreduction for peritoneal carcinoma has high risk for metastasis to ovarium. In this case report, the management consisted of TAH-BSO, frozen section and biopsy of omentum and peritoneum. Collaboration with digestive surgery should have been done to further evaluate pre-surgery diagnostic procedure to locate primary tumor, tumor resection and metastectomy in surgery, considering there was an increase of CA-125 and CEA indicating to primary malignancy in and metastasis from gastrointestinal tract, so proper management can be done.

Survival rate of patient with malignant ovarian tumor depends on the 5-year survival rate of the primary tumor. Prognosis of patient with Krukenberg tumor is very poor with mean survival rate around 3 – 10 months. Only 10% can survive over 2 years after diagnosis. This patient came while in III B stage, so it can be said that it was late stage when diagnosed. In metastasis limited to ovarium, surgery can increase the survival rate.⁹ Based on report from Jiang et al, 5-year survival rate after resection was estimated about 12.1%. Lower rate was reported in a study by Webb et al, with 5-year survival rate around 5.4% in patient with ovarian metastatic tumor from gastrointestinal tract. One of the prognostic factor in Krukenberg tumor is complete tumor resection.¹³ Other factor affecting clinical outcome of the patient is that patient with gastric source of primary tumor had poorer prognosis compared to colorectal or breast primary tumor. This is based to a hypothesis that gastric cancer usually has worse clinical status, like severe anemia and in general have poorer prognosis.¹⁶

CONCLUSION

According to the literature, prognosis of patient with Krukenberg tumor is very poor with mean survival rate of 3 - 10 months. Management of Krukenberg tumor is surgery (primary debulking). Post surgery radiologic evaluation combined with CA 125 tumor marker is very effective in detecting recurrence. Prognosis of signet ring cell ovarian cancer is generally poor, so it is very important to identify correctly and determine the stages from early on in order to give proper management that will benefit the patient. Early diagnosis can increase the survival rate. Confirming diagnosis and management should be done aggressively, if there is suspicion towards malignancy. Possible metastatic tumor from gastrointestinal organ with the diagnosis of Krukenberg tumor should be managed with collaboration with digestive surgery department, and regular follow-up of the patient should be performed so that the course of the disease can be better monitored.

REFERENCES

1. General information about ovarian cancer. American Cancer Society website. Available from: <http://www.cancer.org/cancer/ovariancancer/index>
2. General information about ovarian cancer. John Hopkins Pathology. Available from: <http://ovariancancer.jhmi.edu/home.cfm>.
3. Aziz MF. Gynecological cancer in Indonesia. Indonesia J Gynecol Oncol. 2009;20(1):8-10.
4. Kertosen PA. Angka kejadian kanker ovarium pada wanita menopause di RSUD Dr Soetomo pada tahun 2013-2014. Surabaya: Universitas Airlangga; 2016.
5. Mates IN, Banceanu G, Ionescu M, et al. Features of Krukenberg type tumors-clinical study and review. Chirurgia (Bucur). 2008;103(1):23-38
6. Yakushiji M, Tazaki T, et al. Krukenberg tumors for clinicopathologic analysis in 112 cases. Acta Obstetrica et Gynecologica Japonica. 1987;39:479-85.
7. Haddad F, Meryem EL, Hliwa W, et al. Krukenberg tumor: Report of six cases. Gastroenterol Hepatol Open Access. 2015;2(1): 00031
8. Nirmal A, Kumar S, Jha J. Krukenberg tumour of the ovary in young female: A case report. Int. J. Curr Res Med Sci. 2016;2(10):60-4.
9. Das M, Shehata F, Son WY, Tulandi T, Holzer H. Ovarian reserve and response to IVF and in vitro maturation treatment following chemotherapy. Hum Reprod. 2012;27(8):2509-14.
10. Cheong JH, Hyung WJ, Chen J, et al. Survival benefit of metastasectomy for Krukenberg tumors from gastric cancer. Gynecol Oncol. 2004;94:477-82.
11. Sugarbaker PH. Peritoneal carcinomatosis: Natural history and rational therapeutic interventions using intraperitoneal chemotherapy. Cancer Treat Res 1996;81:149-68
12. Chen LY, Fu CH, Lu HN, et al. Treatment of Krukenberg tumor with hyperthermic intraperitoneal chemotherapy: a report of three cases. J Med Sci 2016;36(5):197-20
13. Cheong JH, Hyung WJ, Chen J, et al. Survival benefit of metastasectomy for Krukenberg tumors from gastric cancer. Gynecol Oncol. 2004;94:477-82.
14. Yildirim et al. The accuracy of frozen section in the diagnosis of malignant adnexal masses. Dicle Medical Journal. 2016;43(1):18-21
15. Mutch DG, Prat J. FIGO staging for ovarian, fallopian tube and peritoneal cancer. Gynecology. 2014;133(3):401-4.
16. Lee KR, Young RH, et al. The distinction between primary and metastatic mucinous carcinomas of the ovary. The American Journal of Surgical Pathology. 2003;27:281-92.